

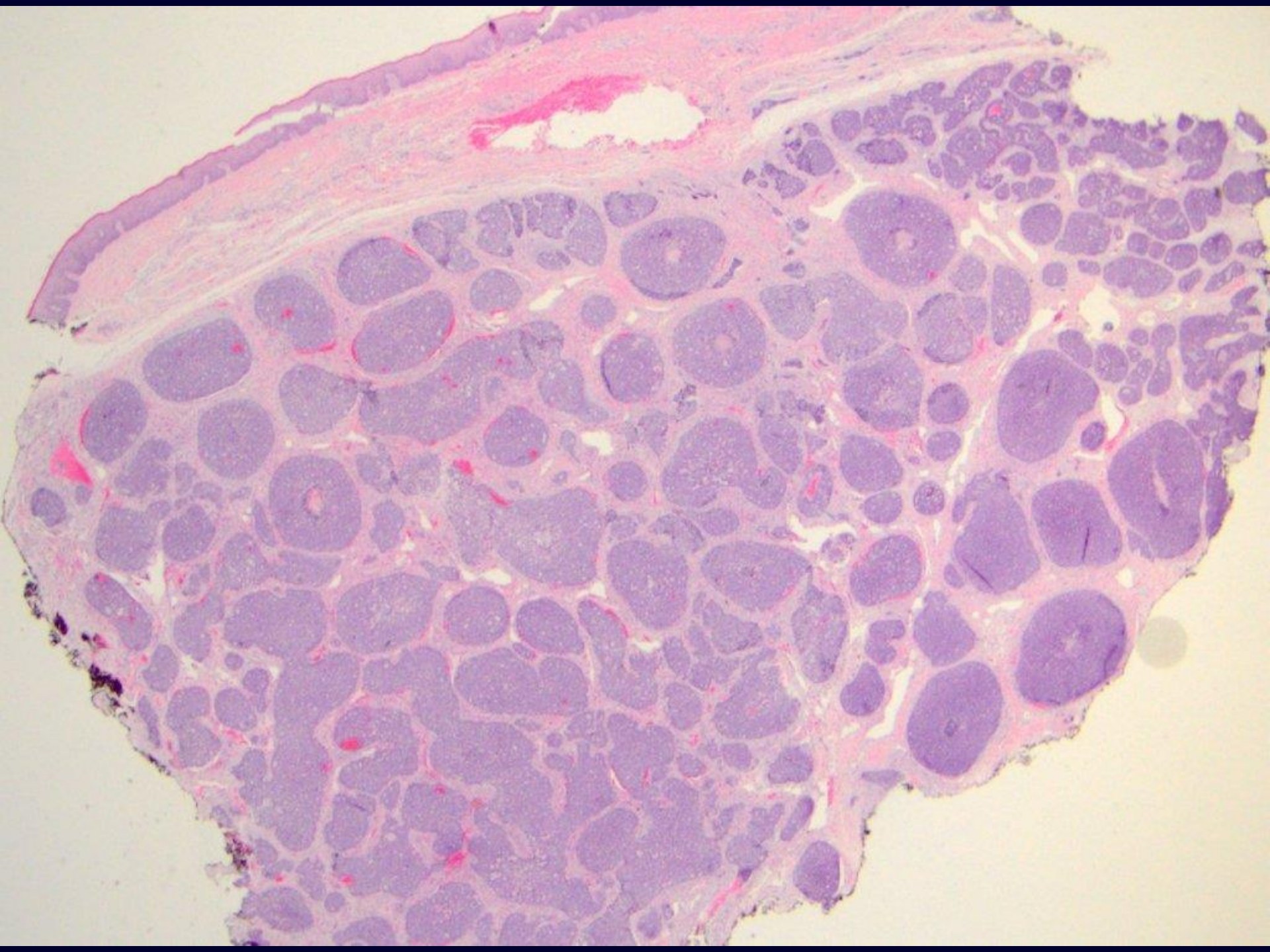
Oral Histopathology

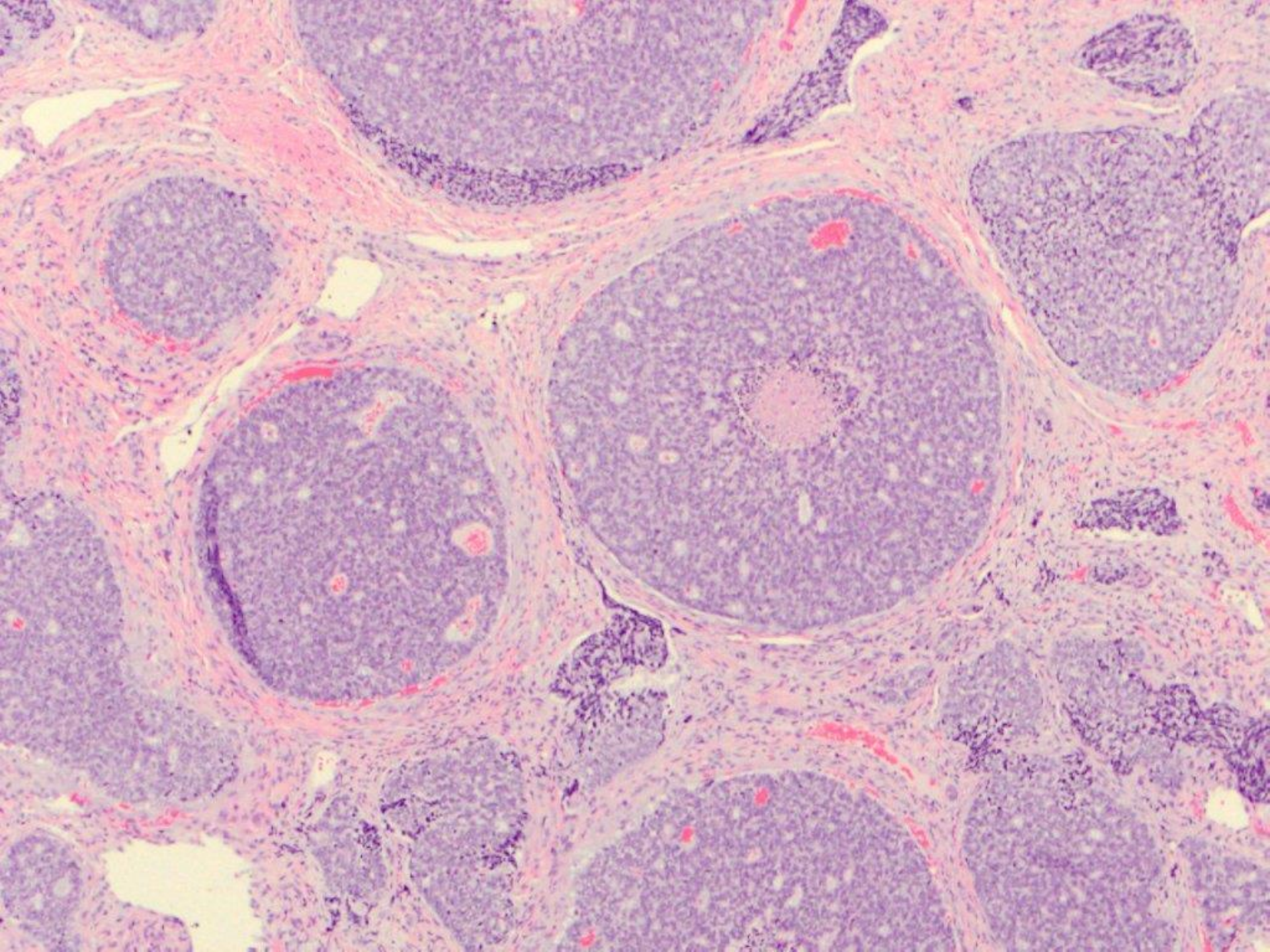
Series 44

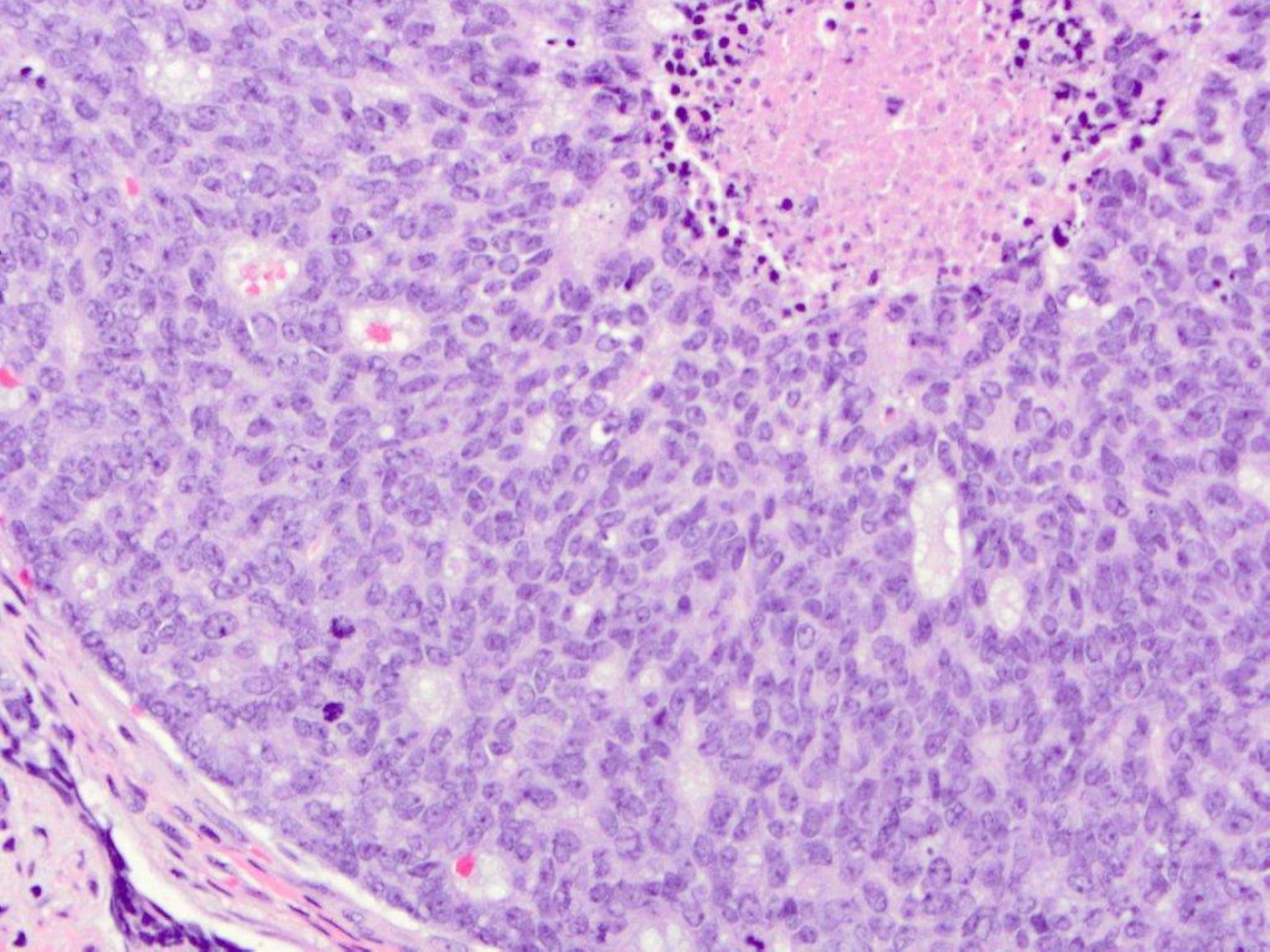
DAVID E. KLINGMAN, DMD

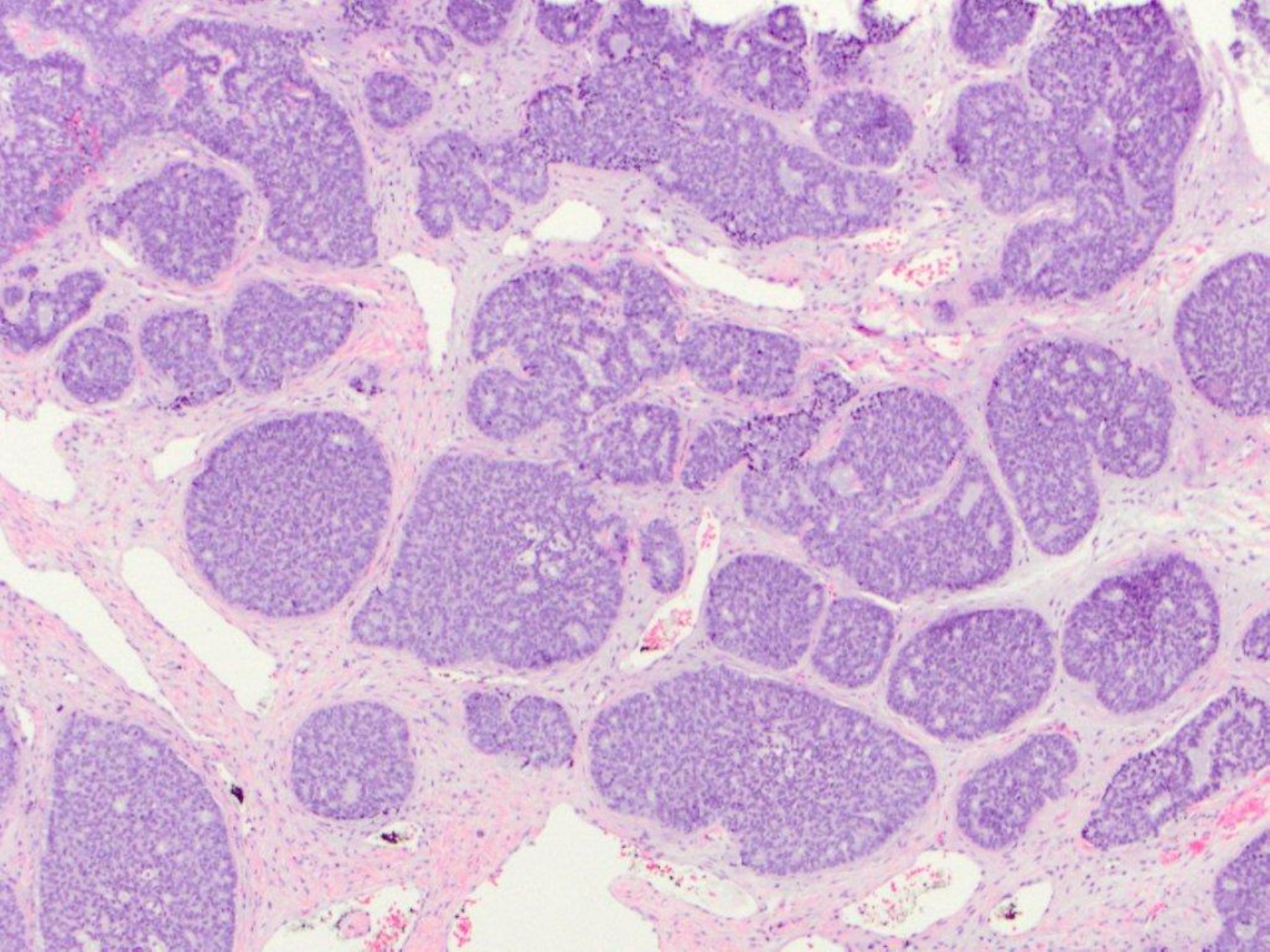
Diplomate, American Board of Oral and Maxillofacial Pathology

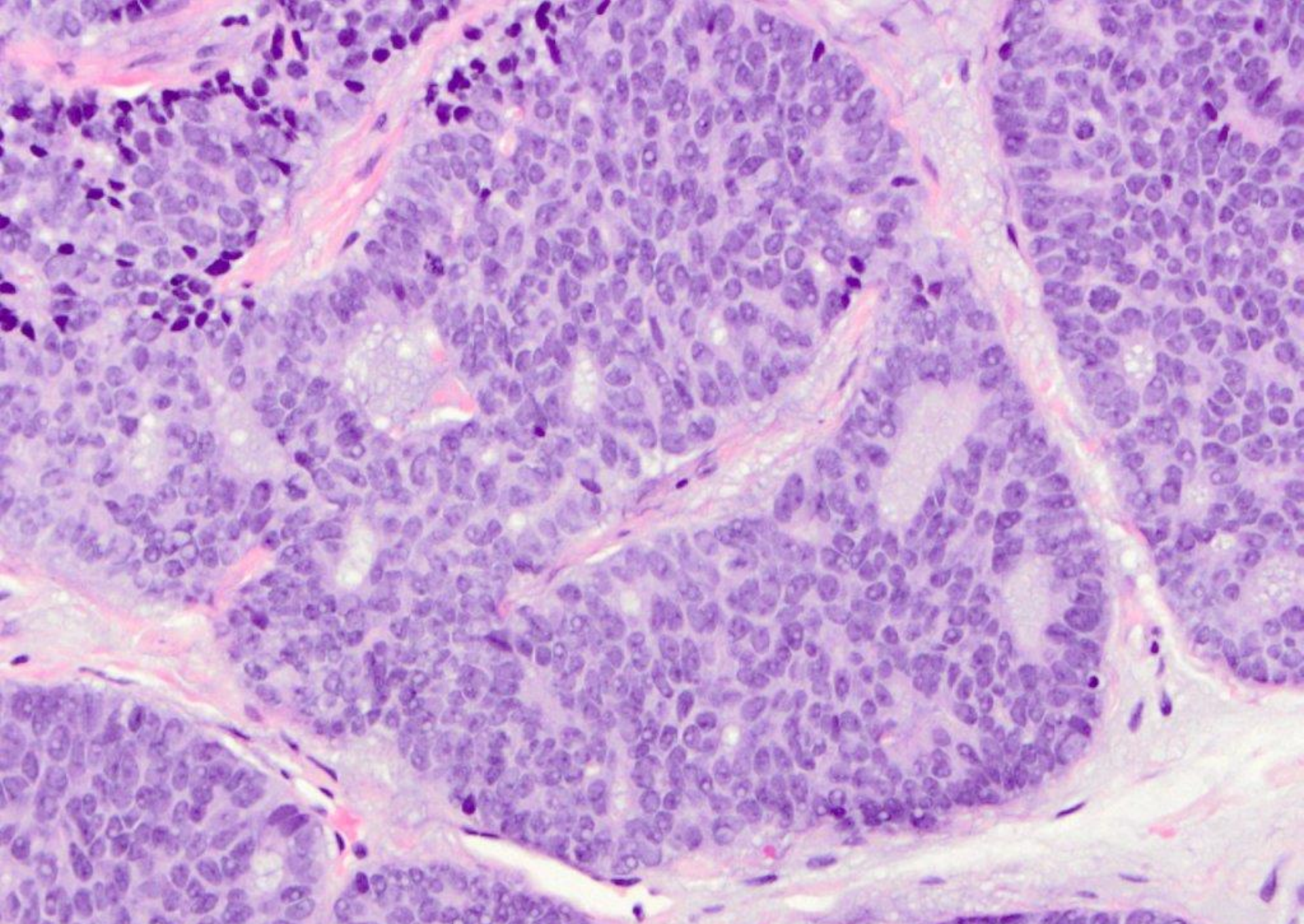
Diplomate, American Board of General Dentistry



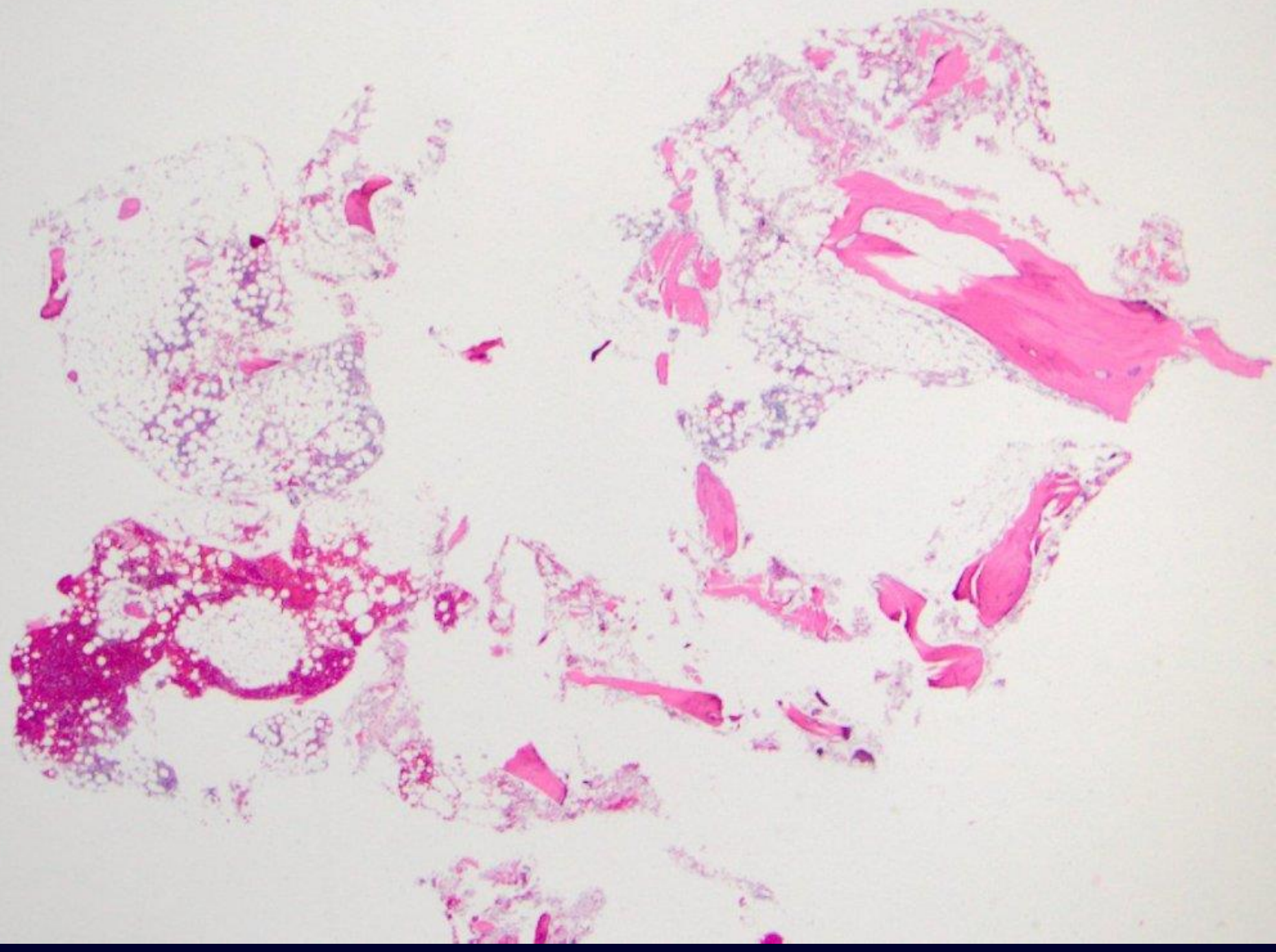


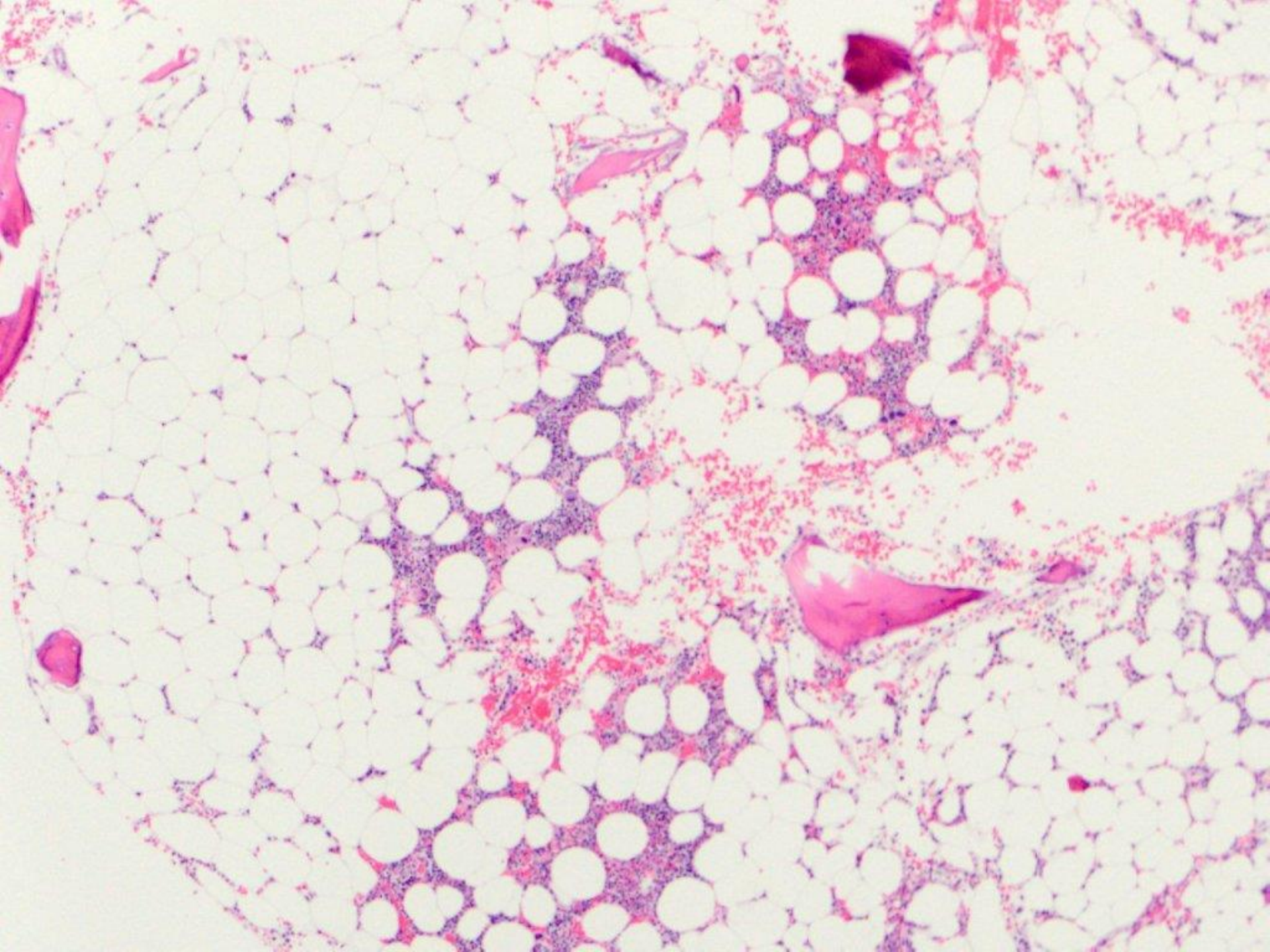


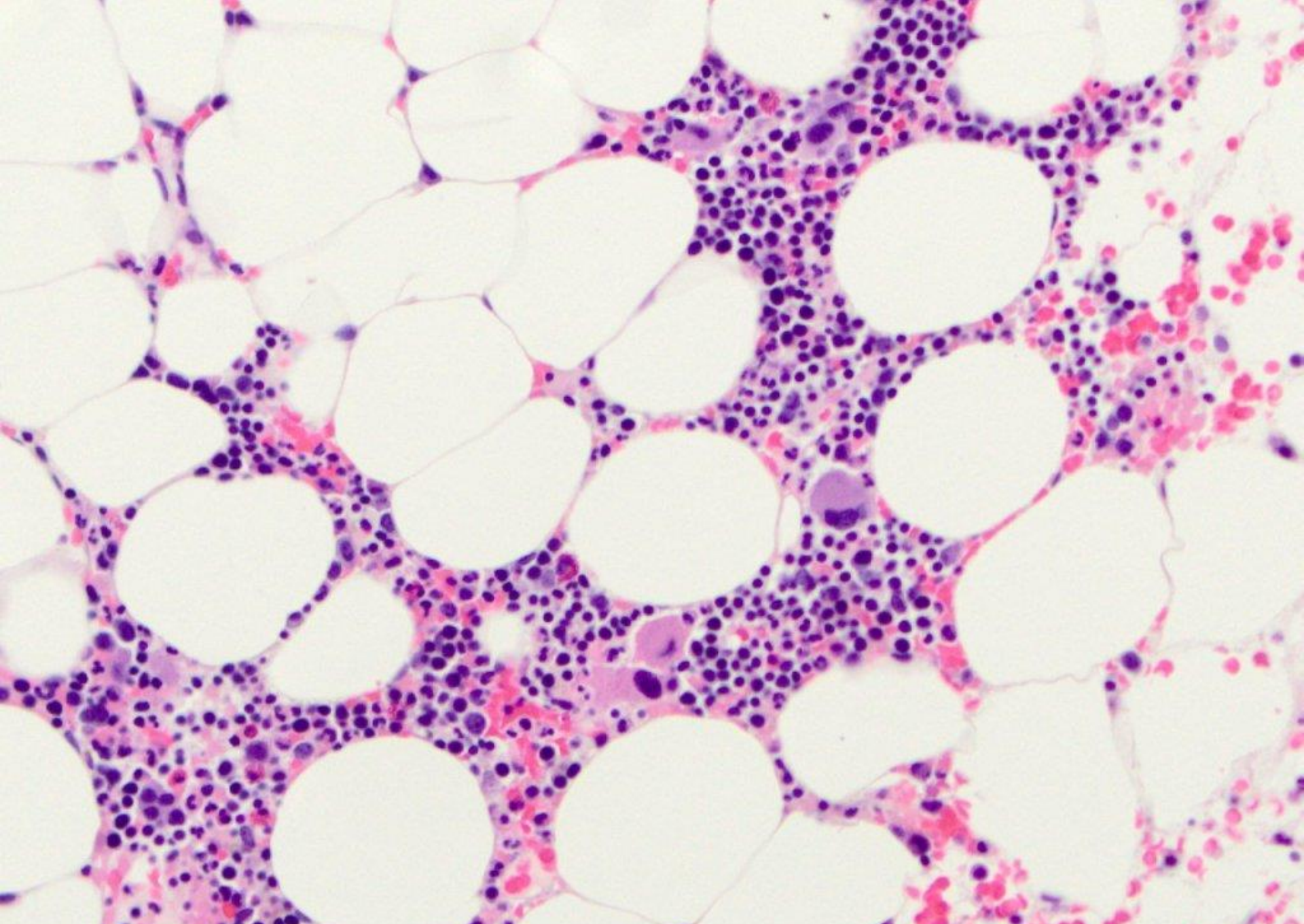




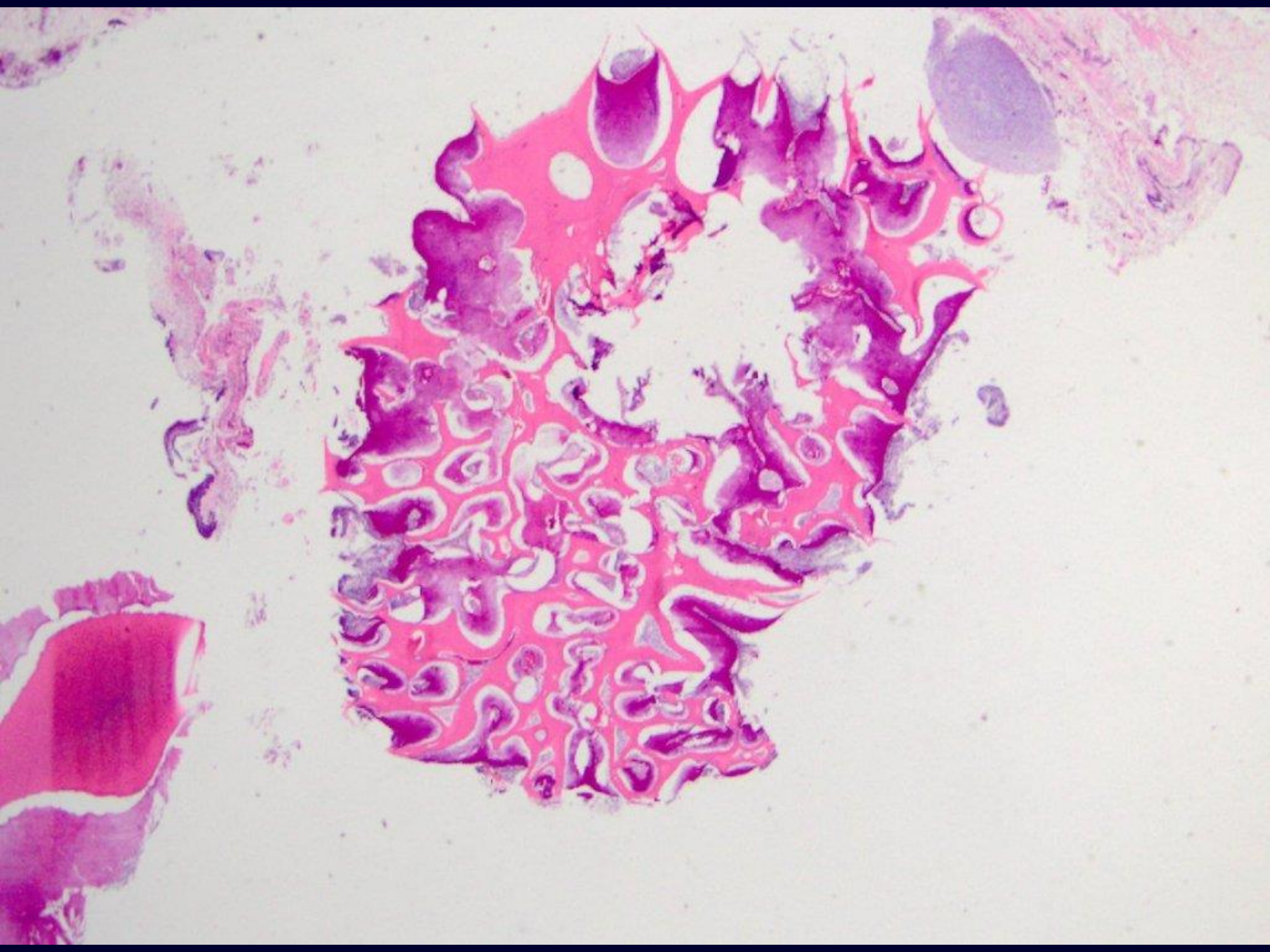
adenoid cystic carcinoma, solid variant

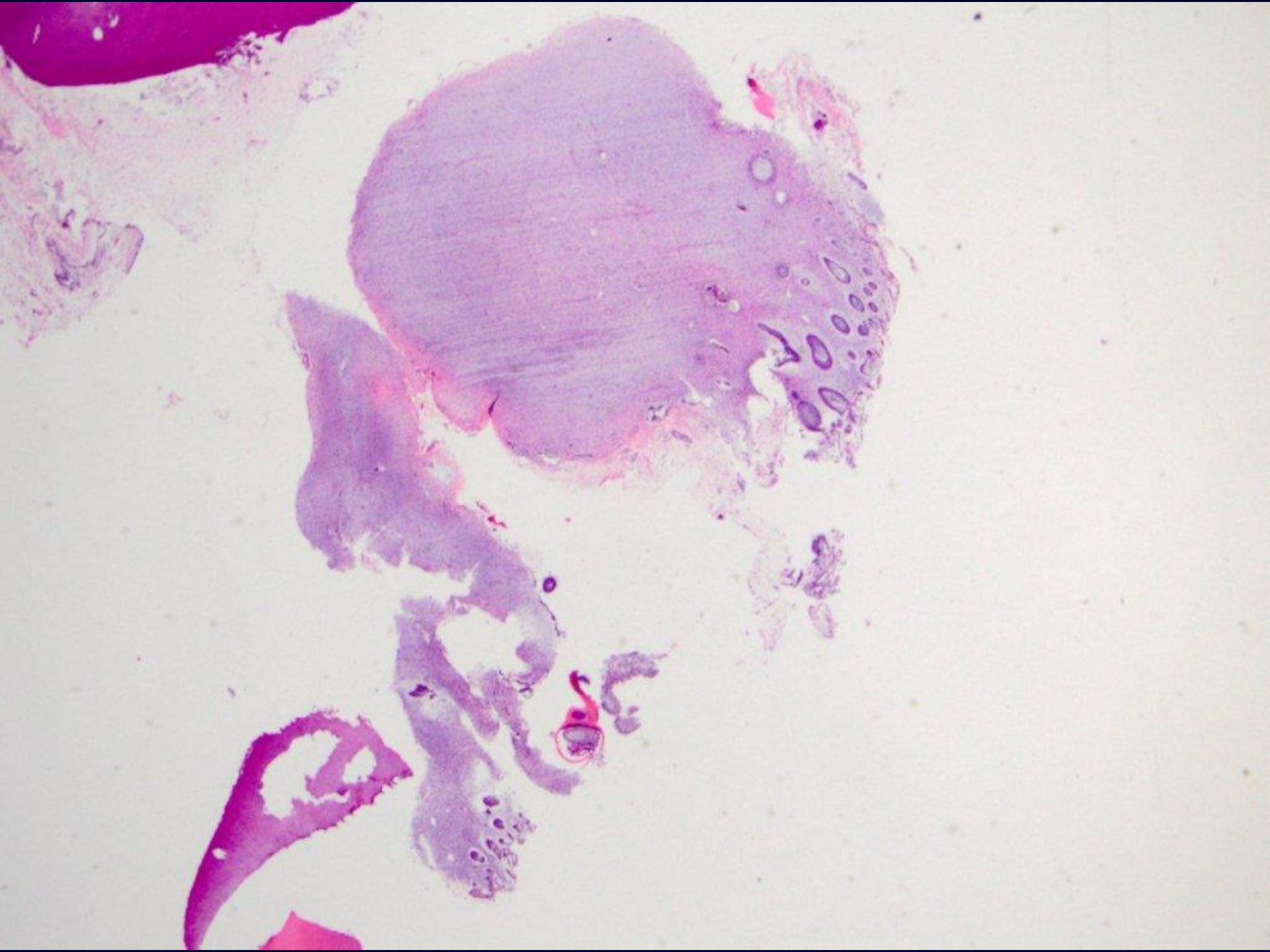


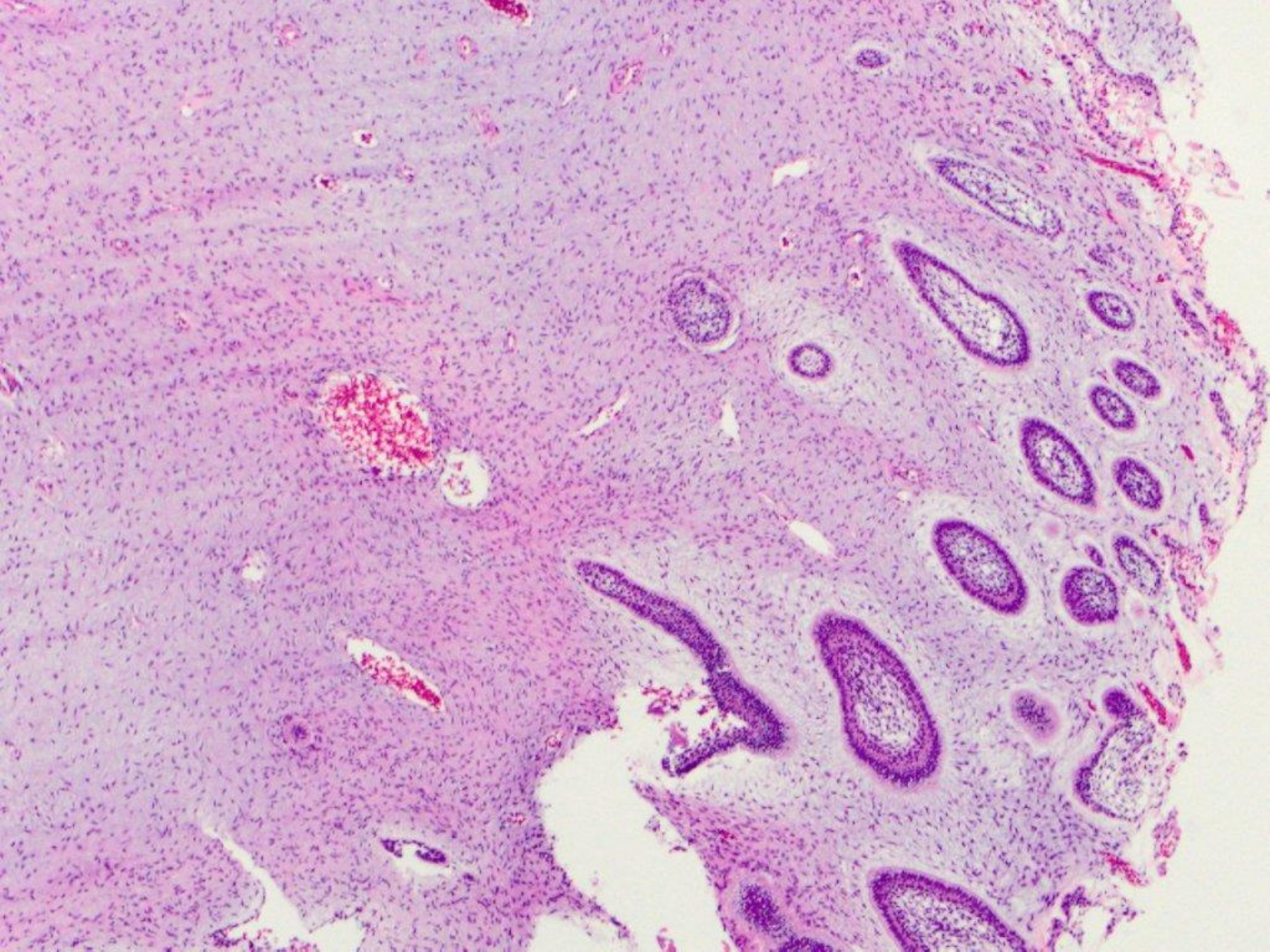


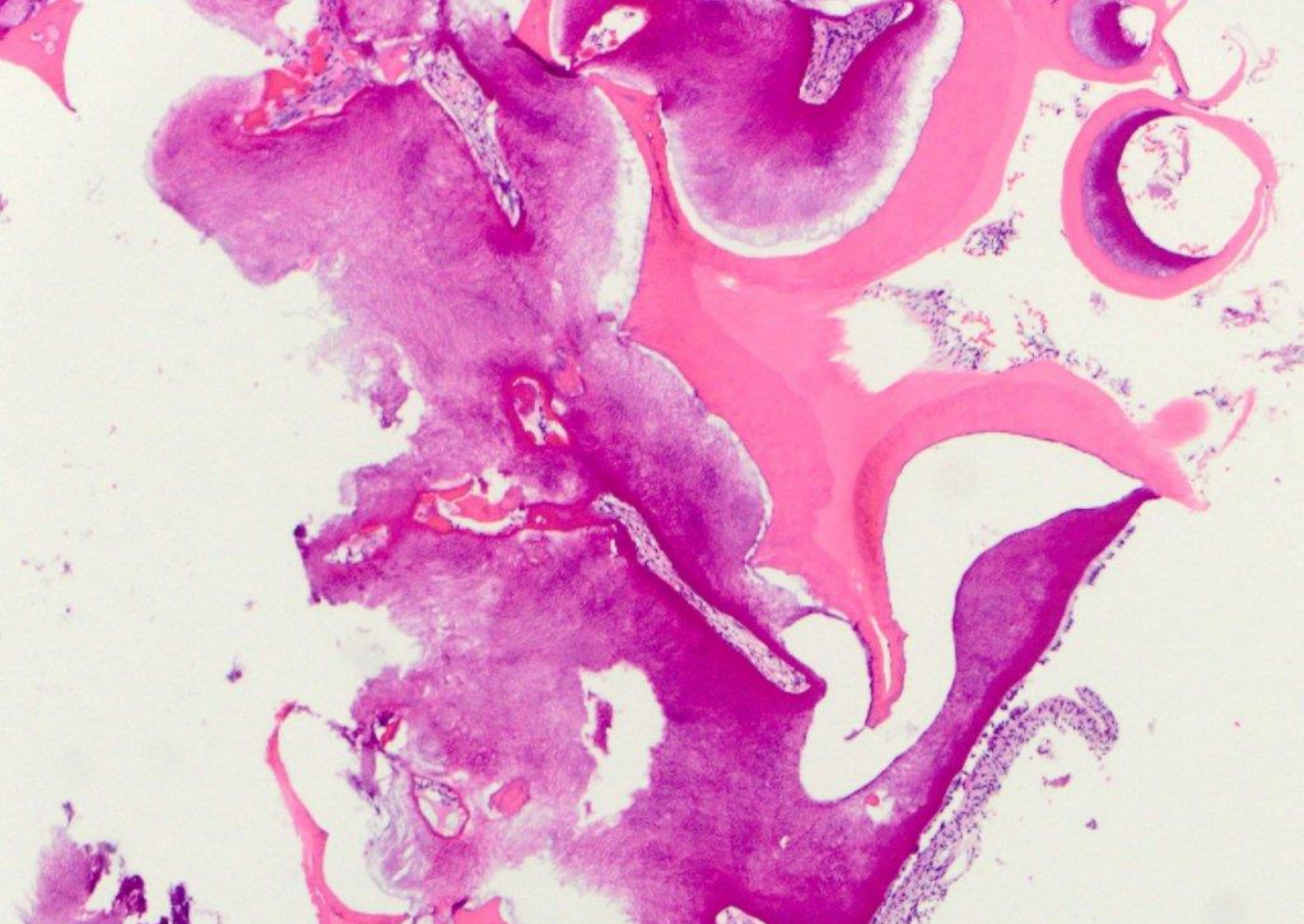


osteoporotic bone marrow defect

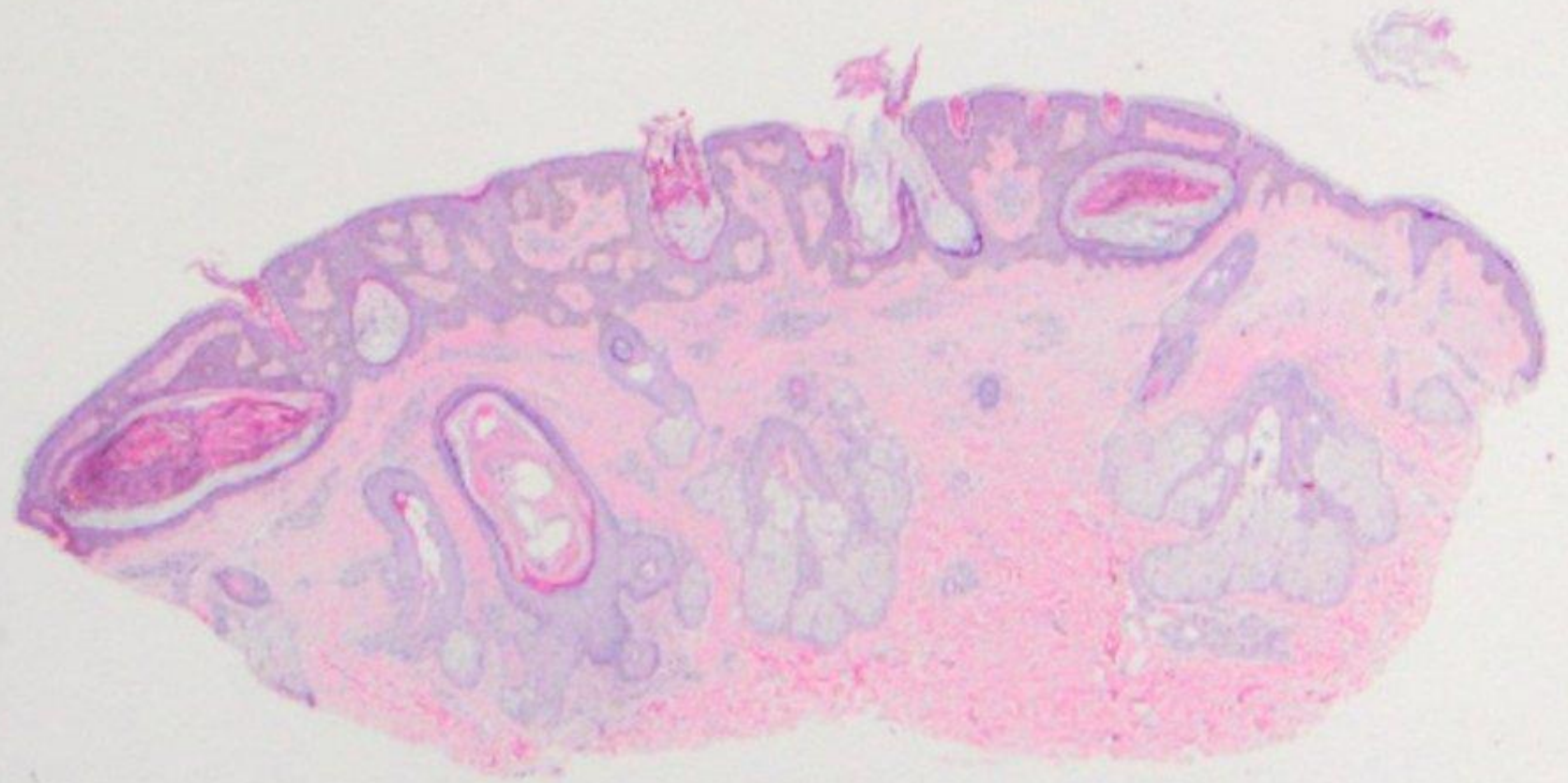


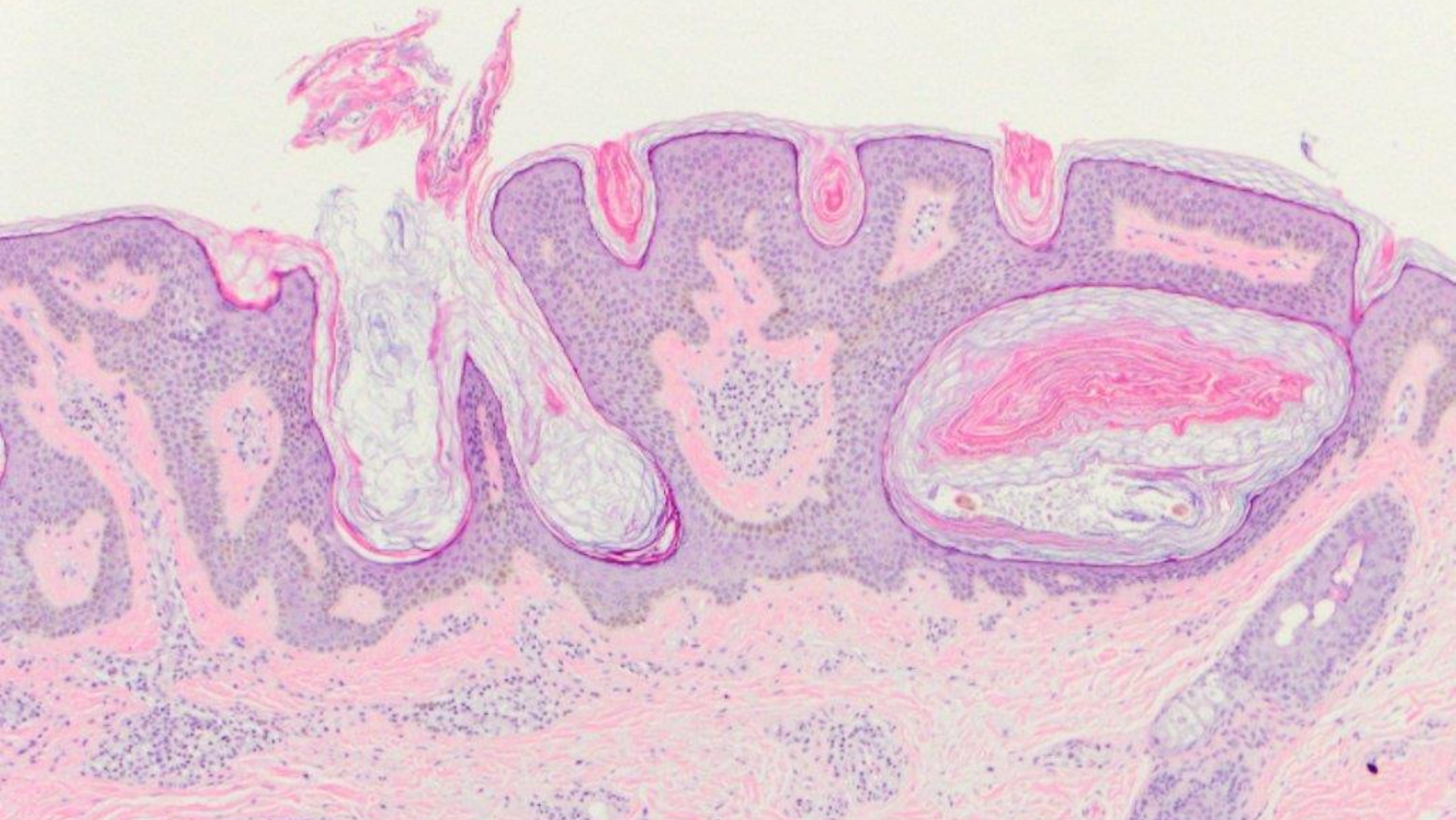




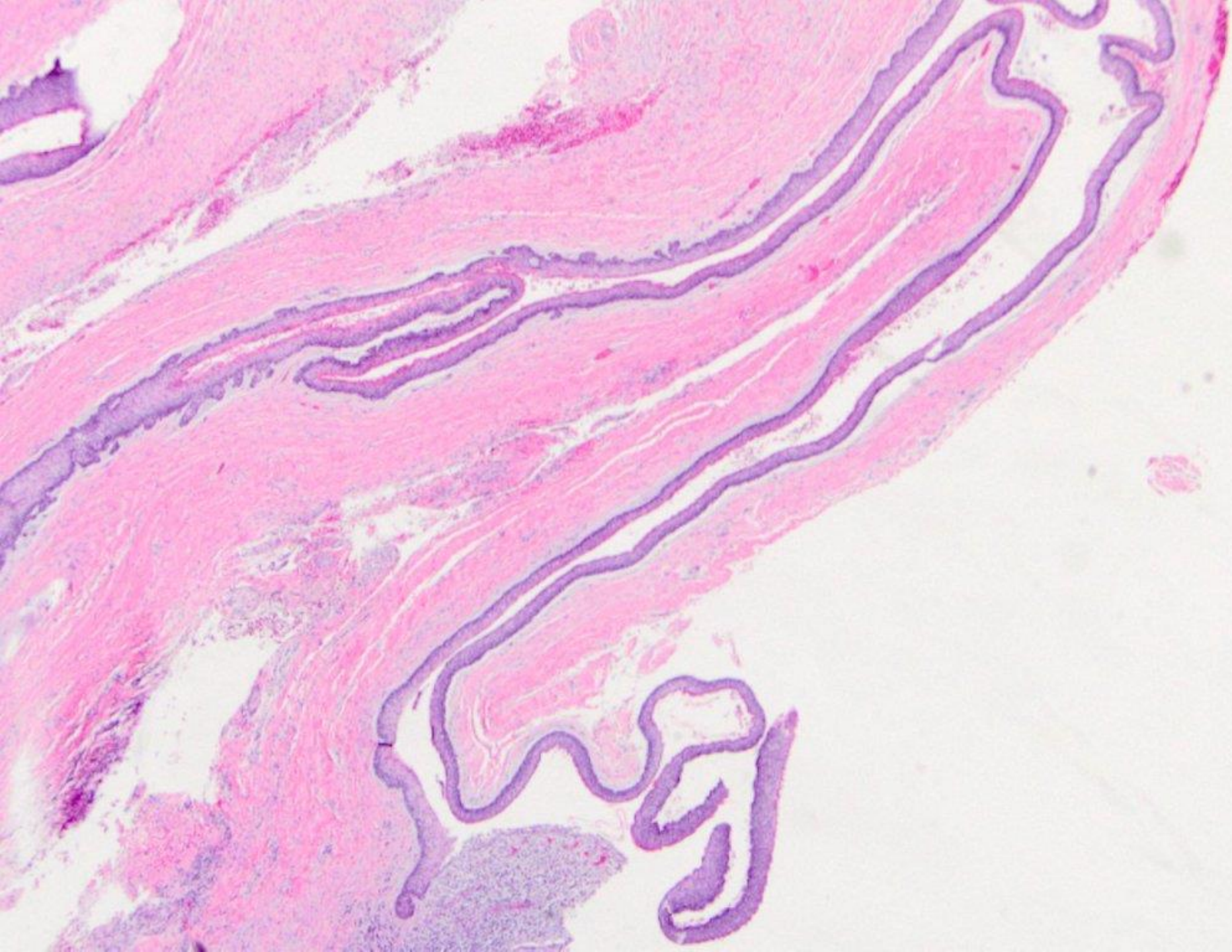


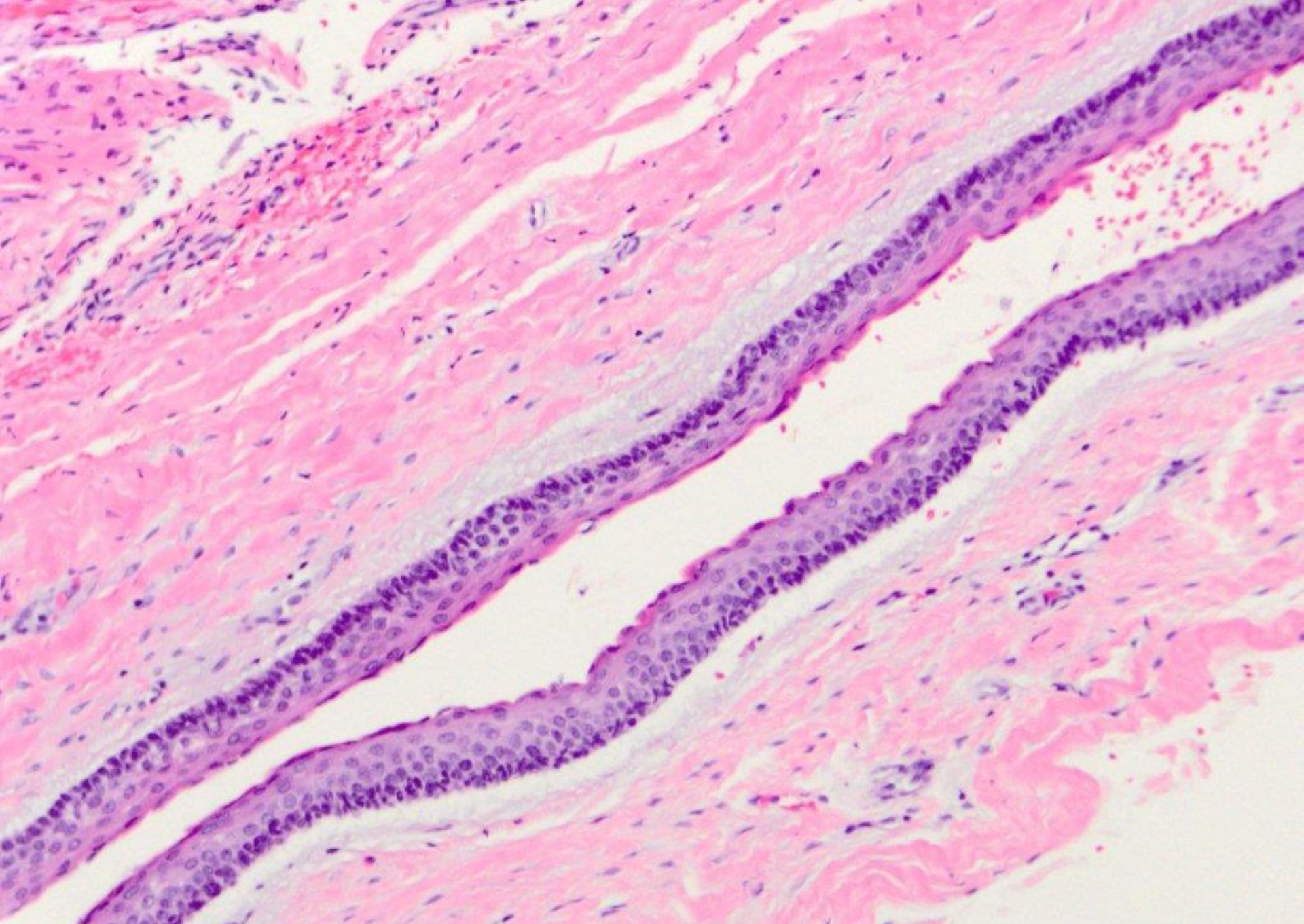
ameloblastic fibro-odontoma



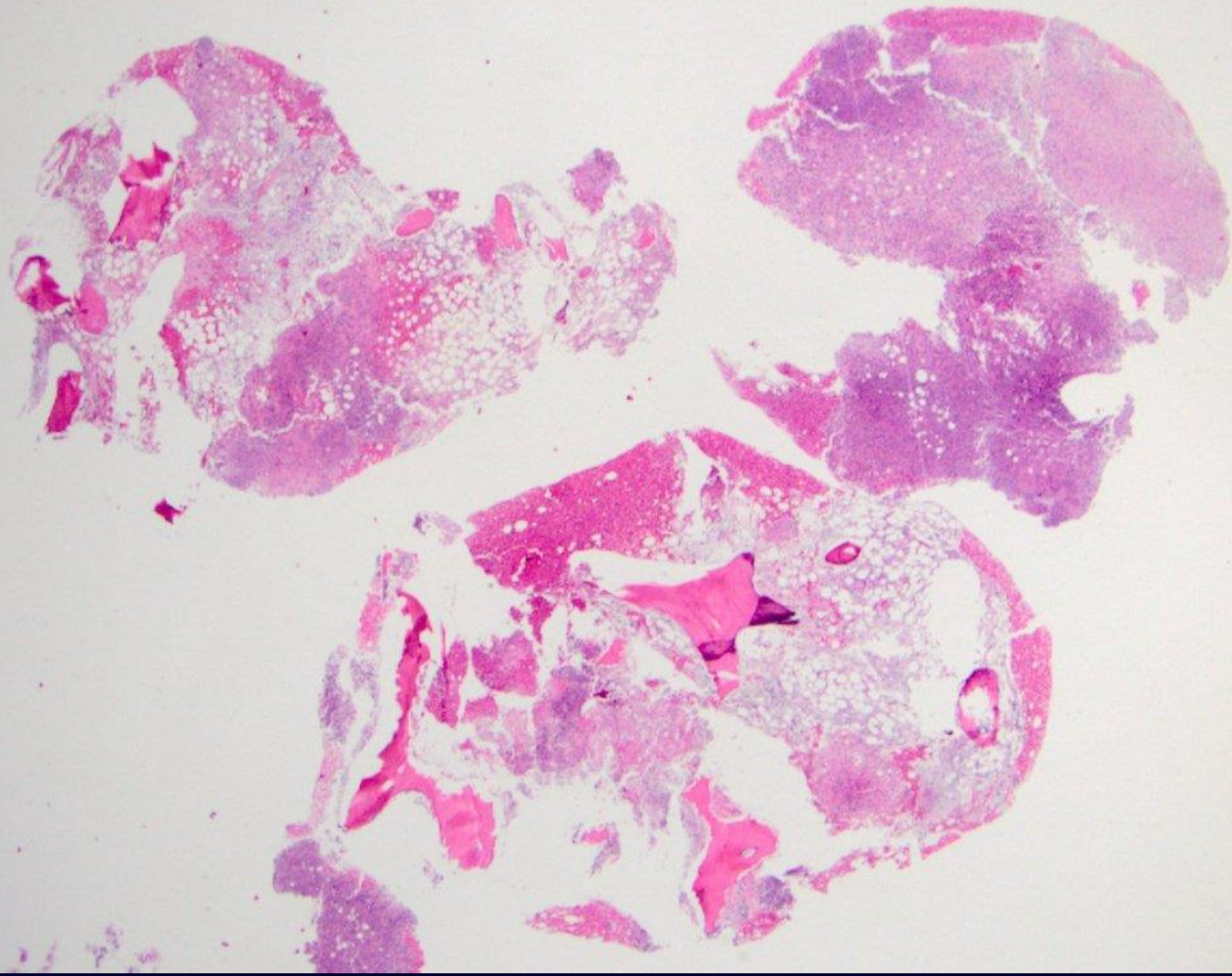


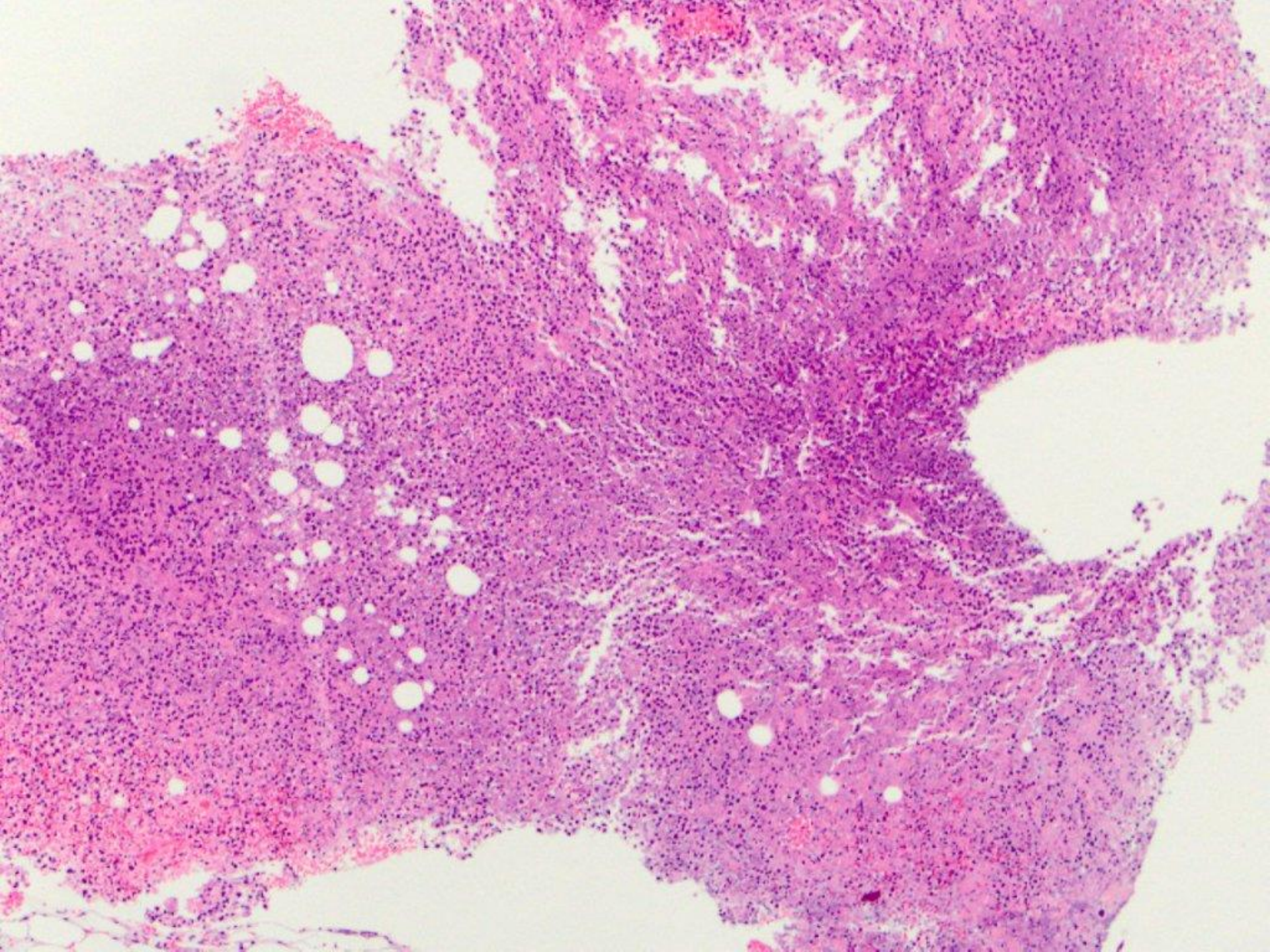
seborrheic keratosis

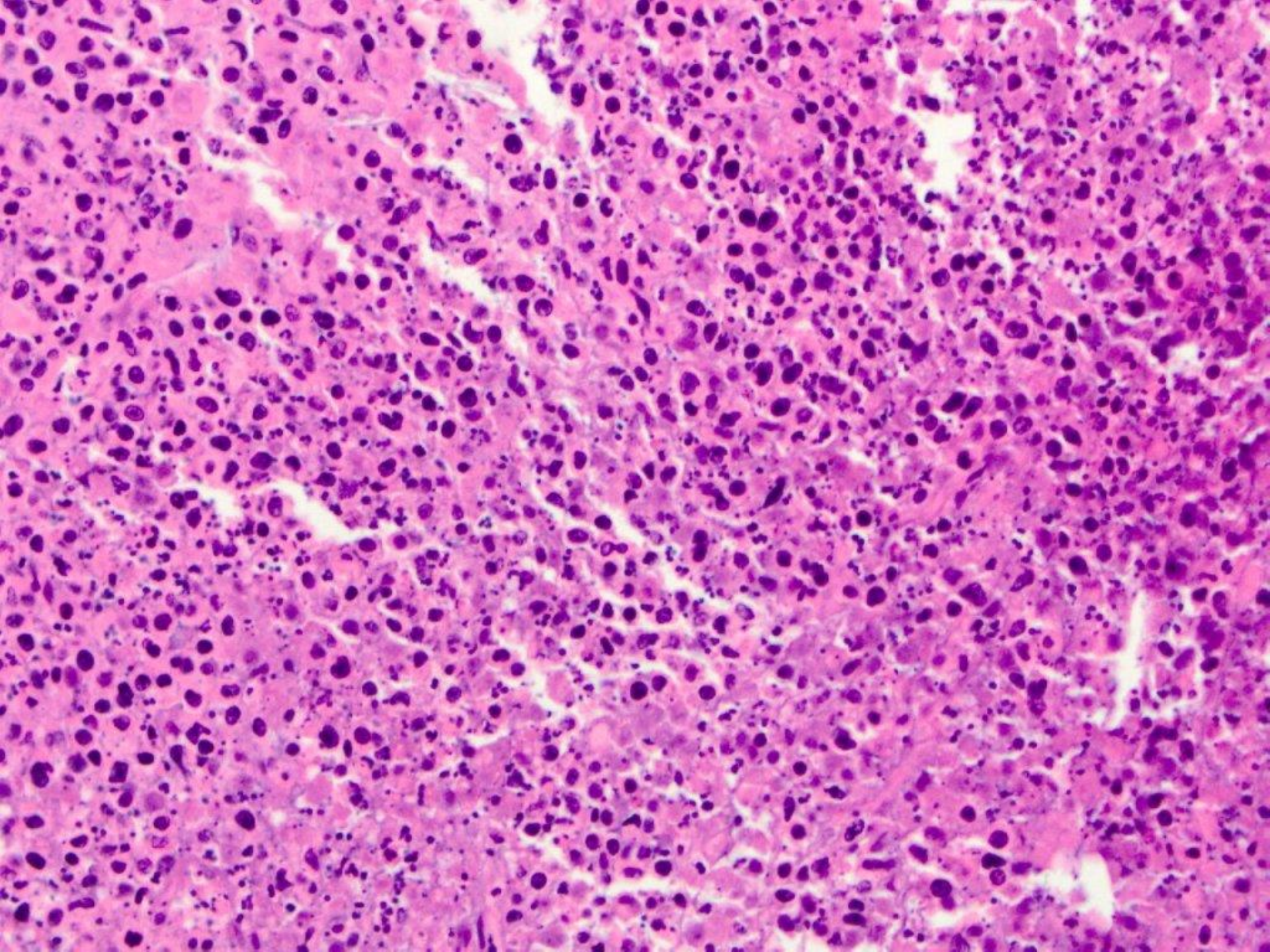


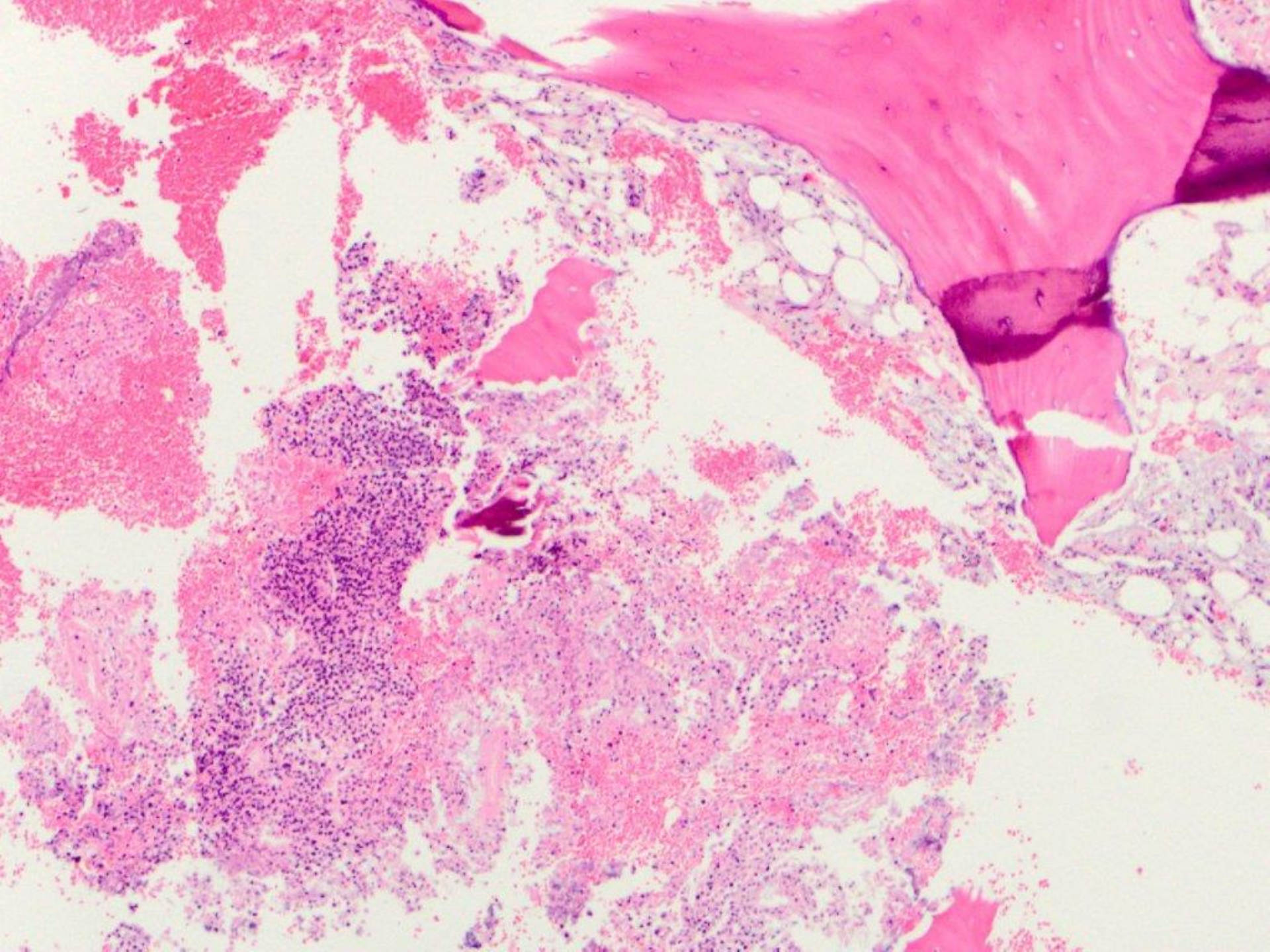


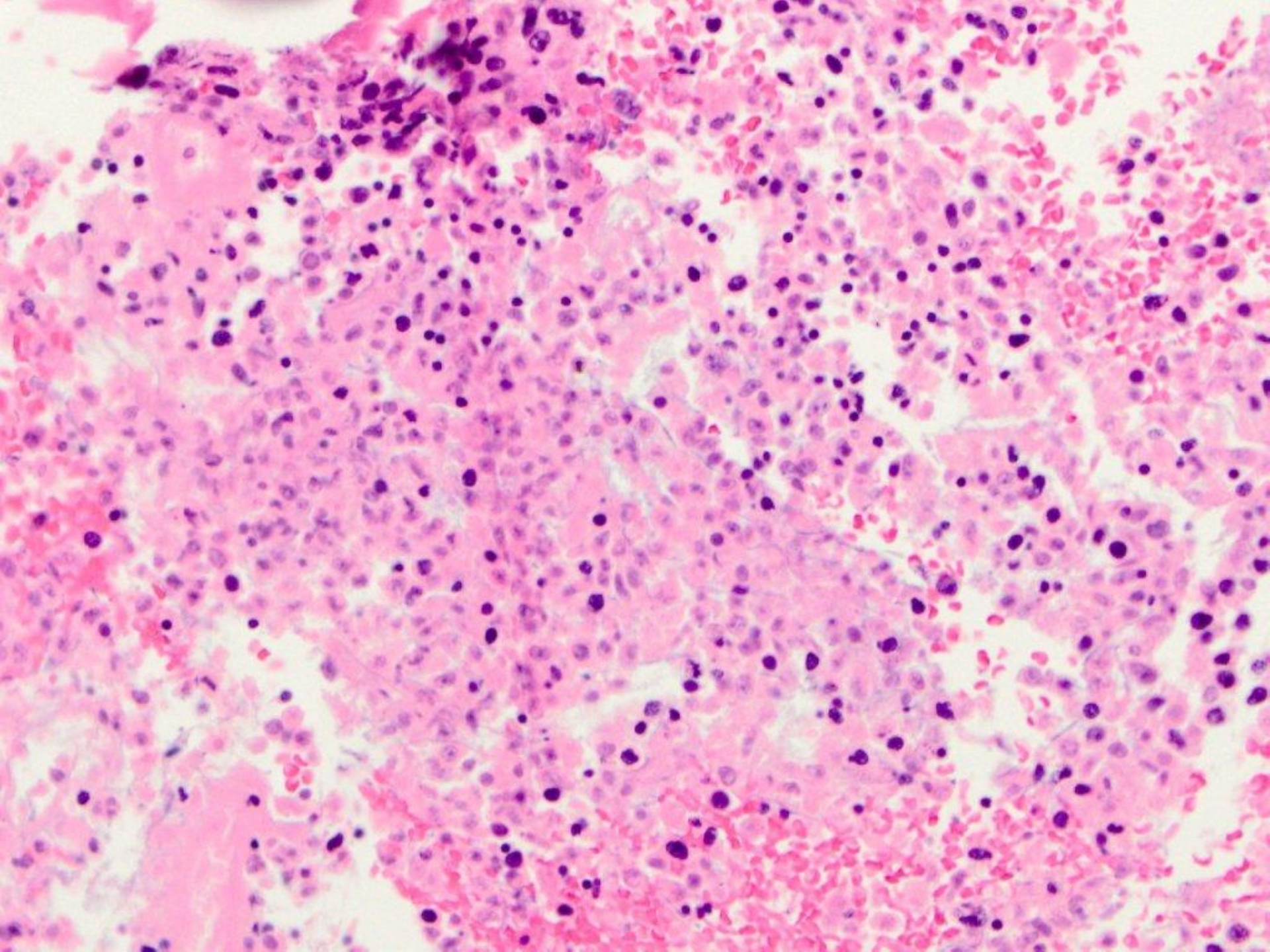
odontogenic keratocyst



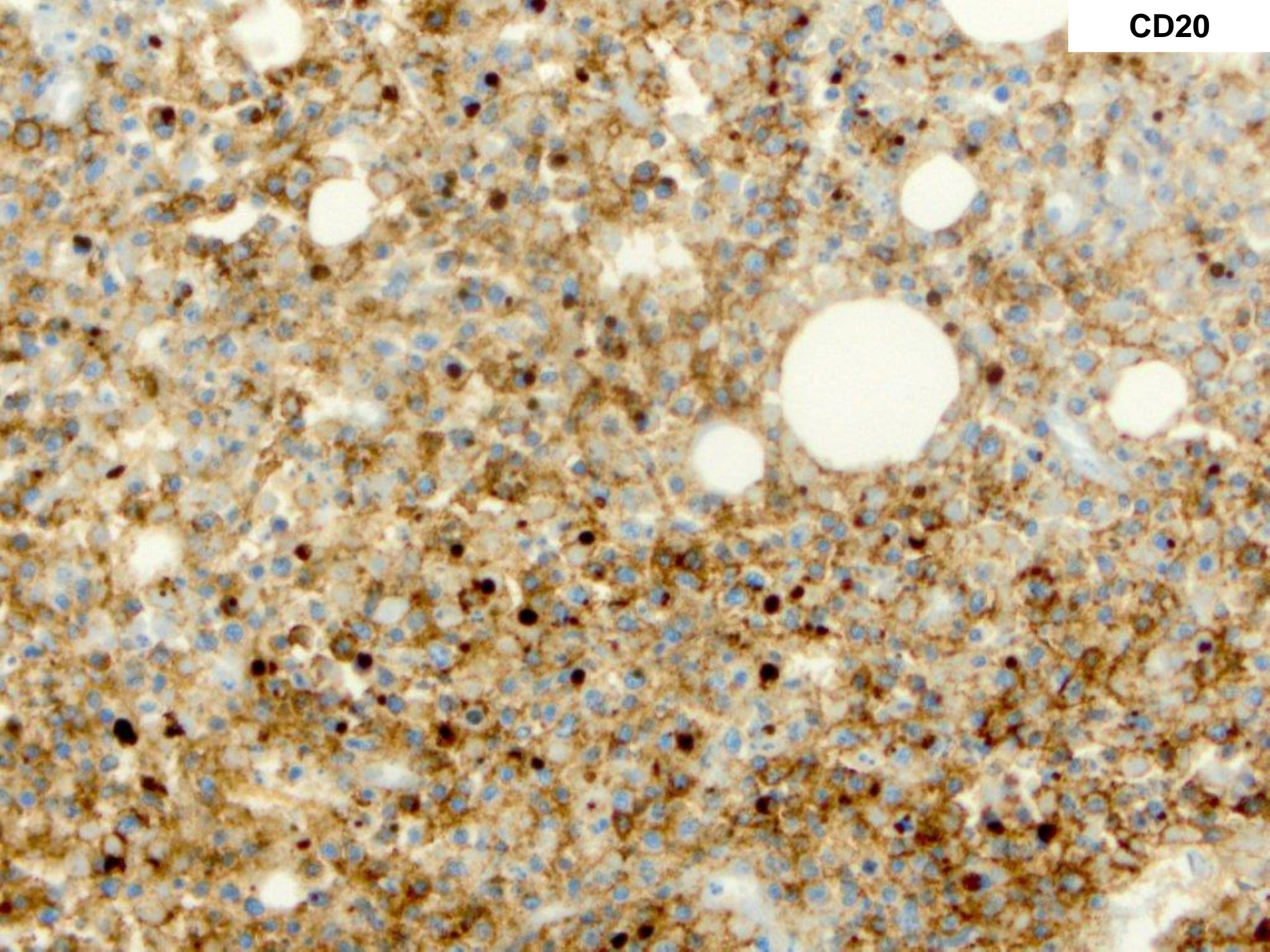




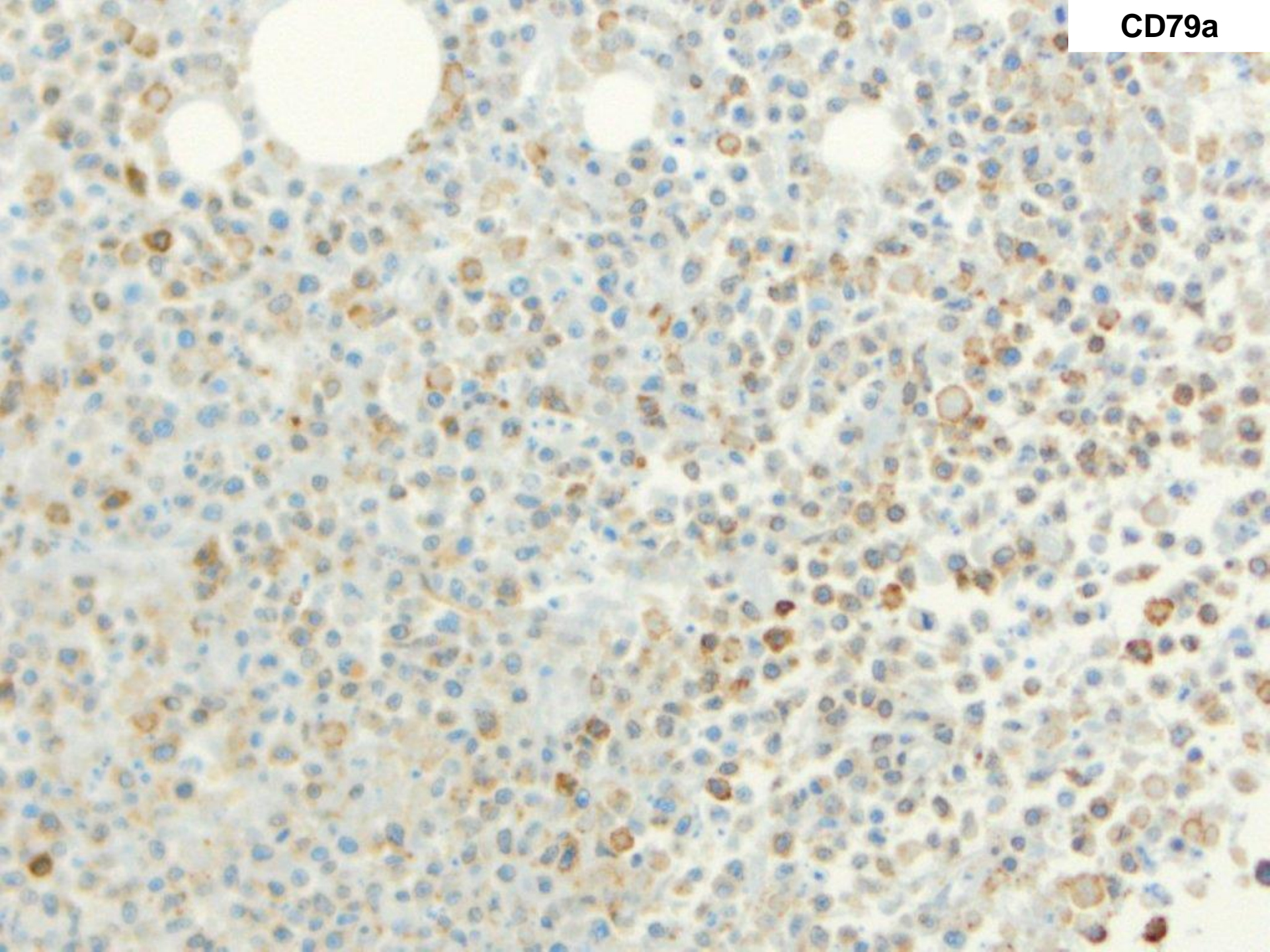




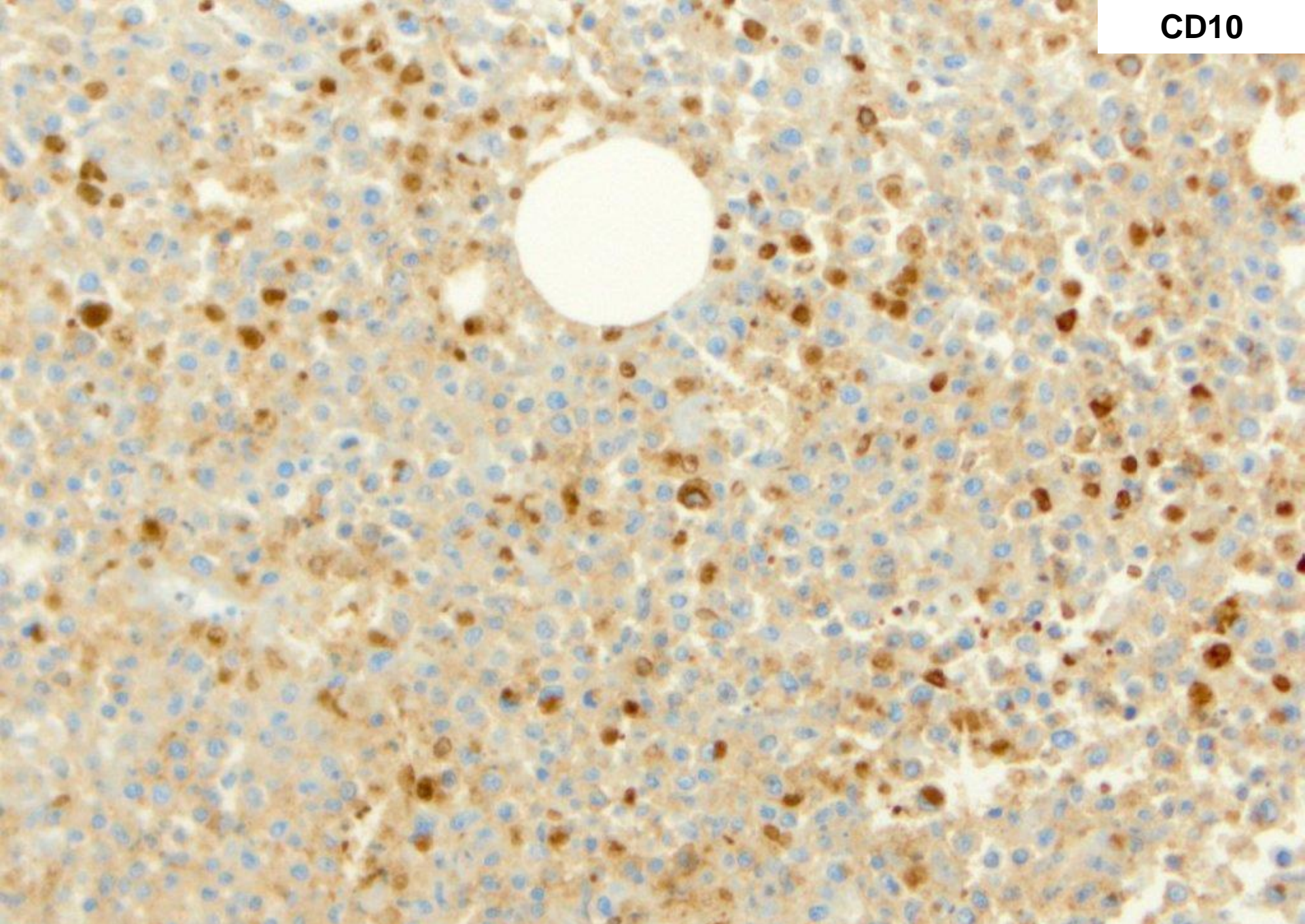
CD20



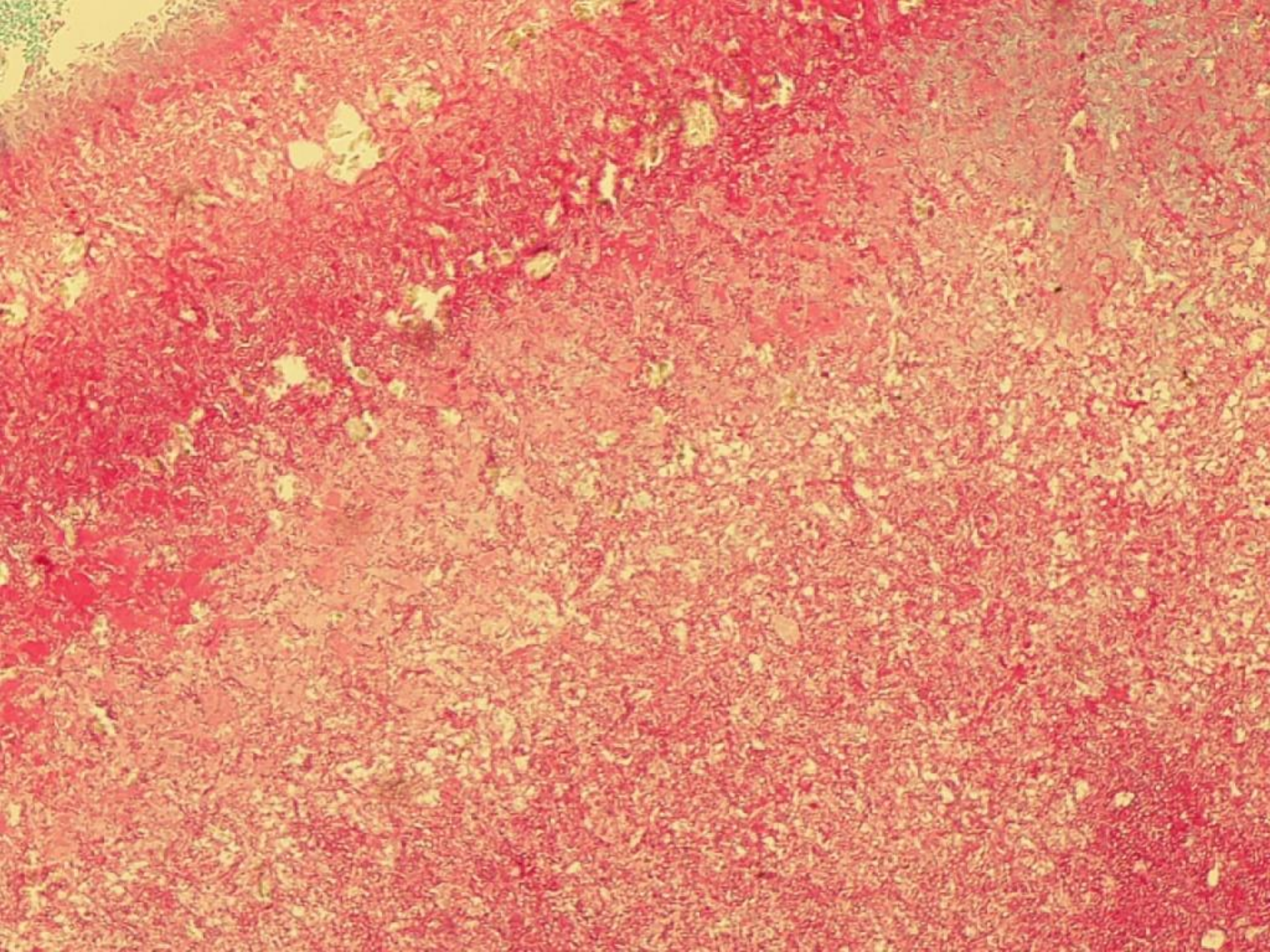
CD79a

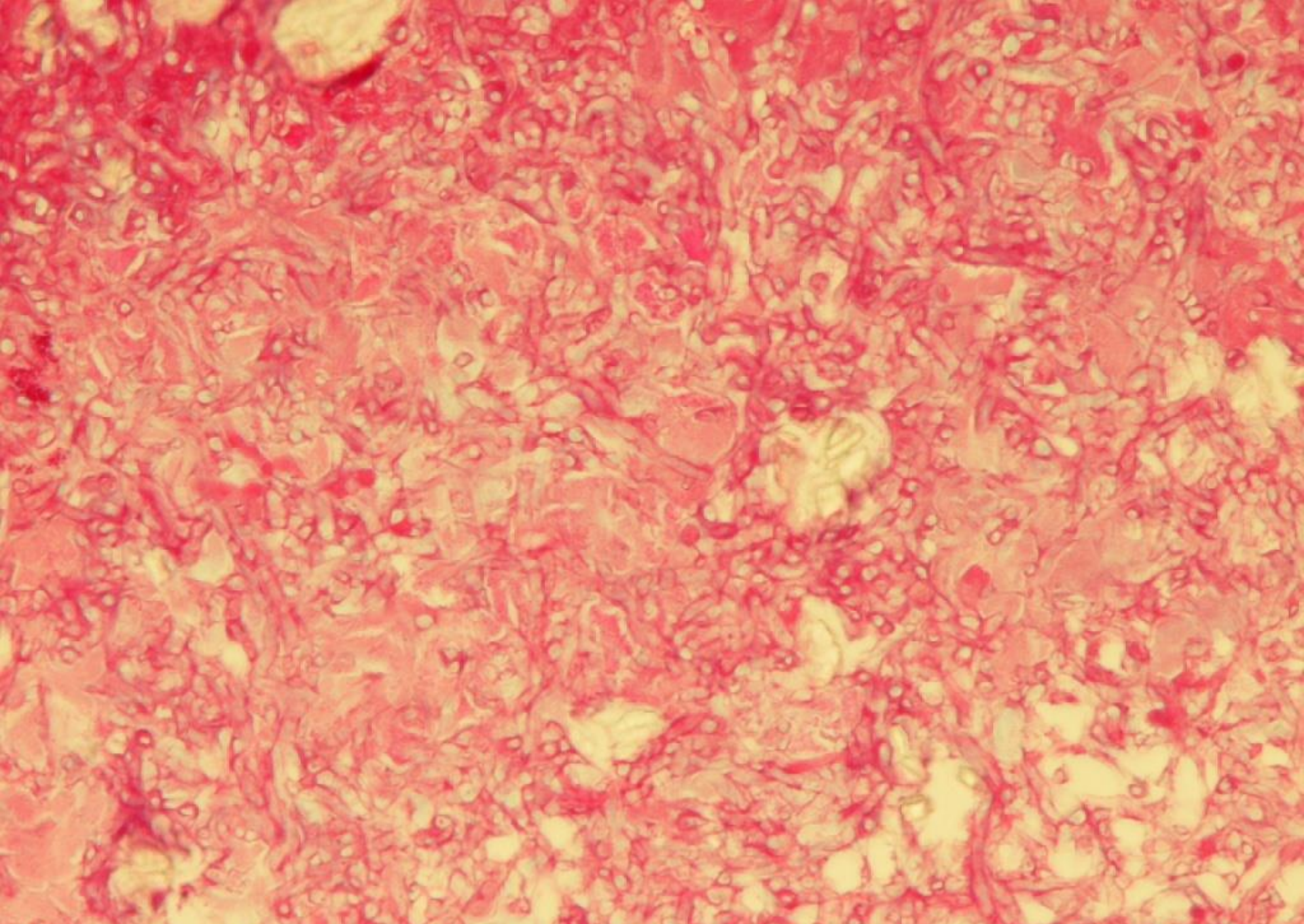


CD10




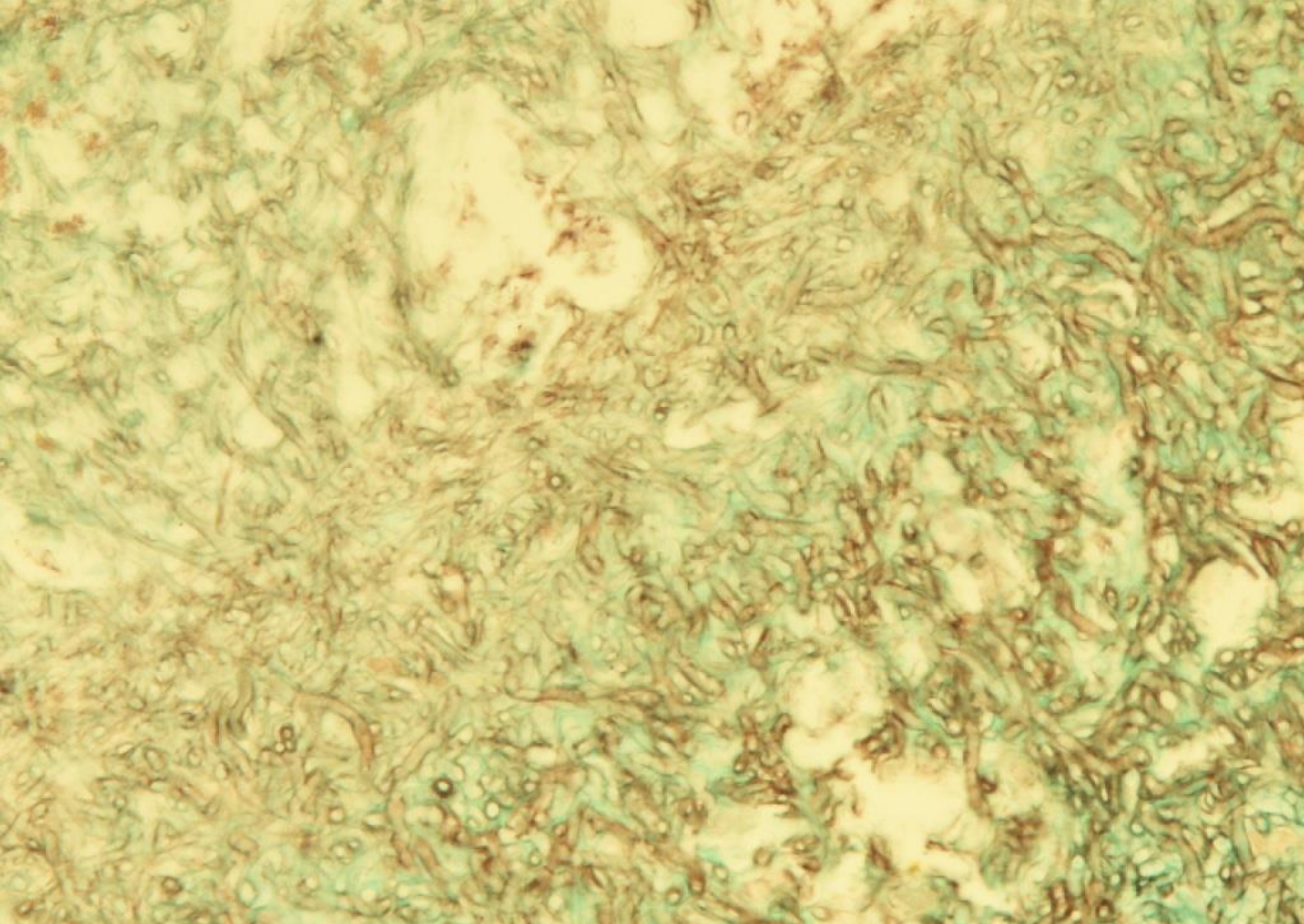
malignant lymphoproliferative process, abundant necrosis, c/w DLBCL



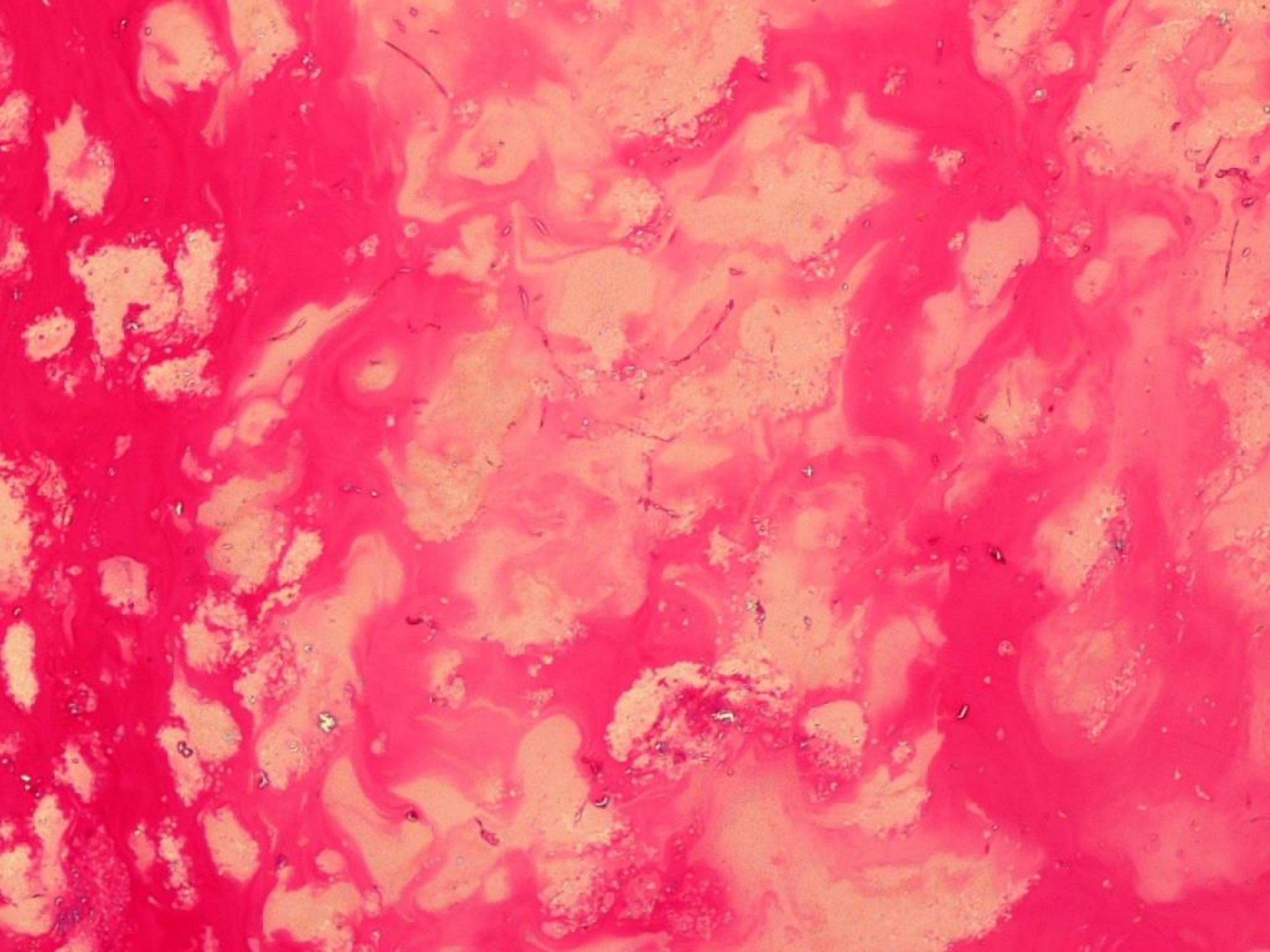

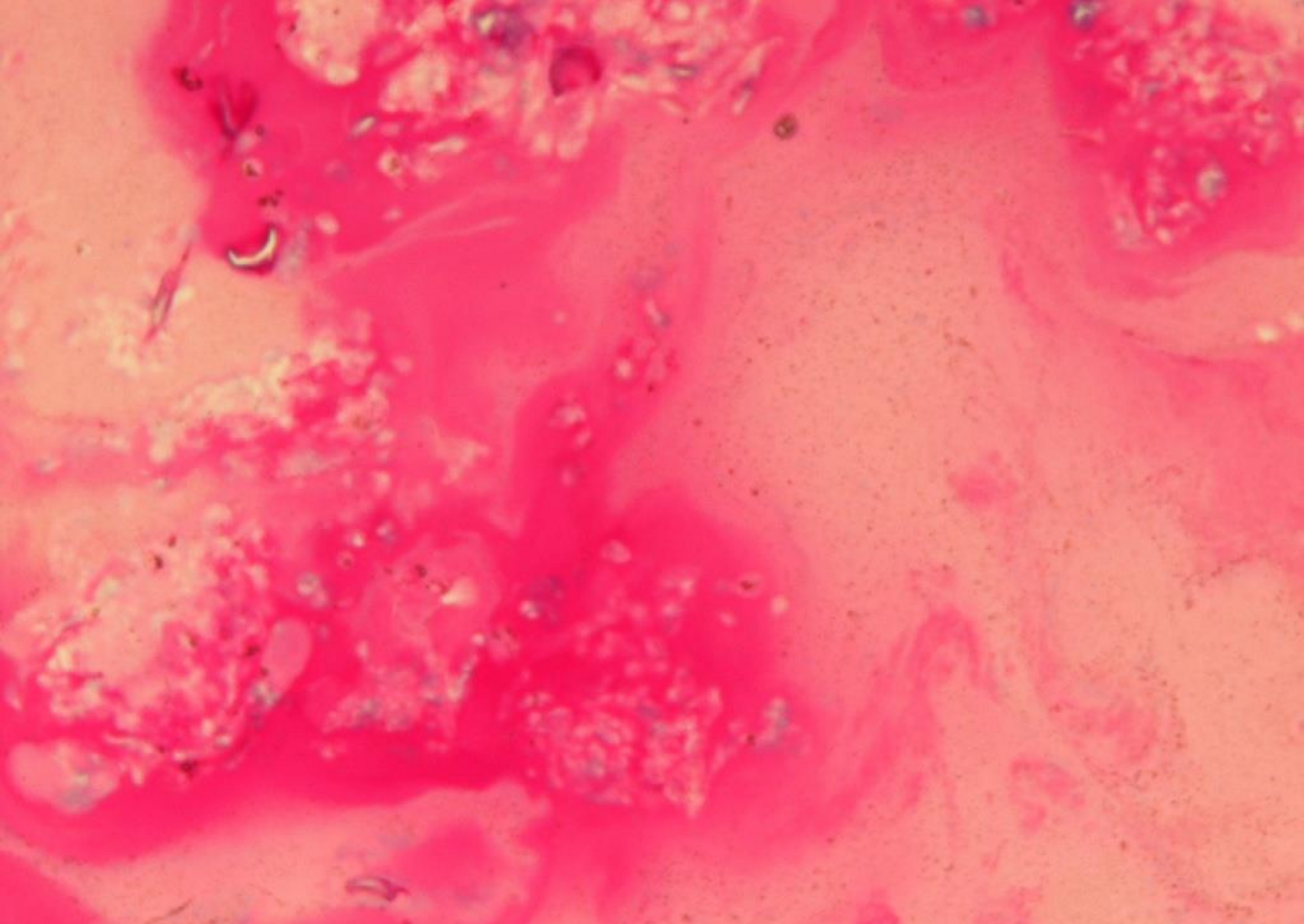mycetoma, c/w aspergillosis [PAS stain]



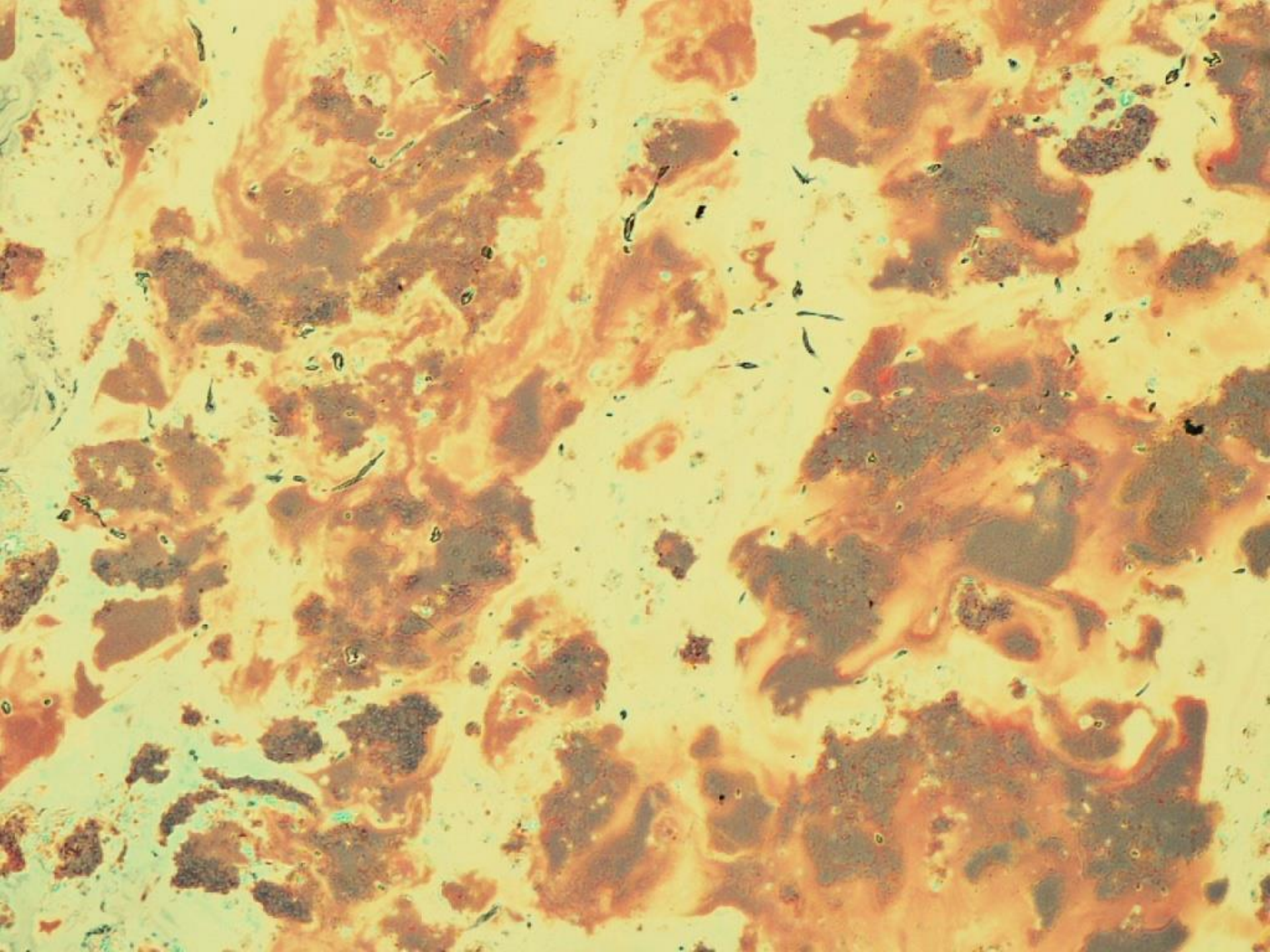


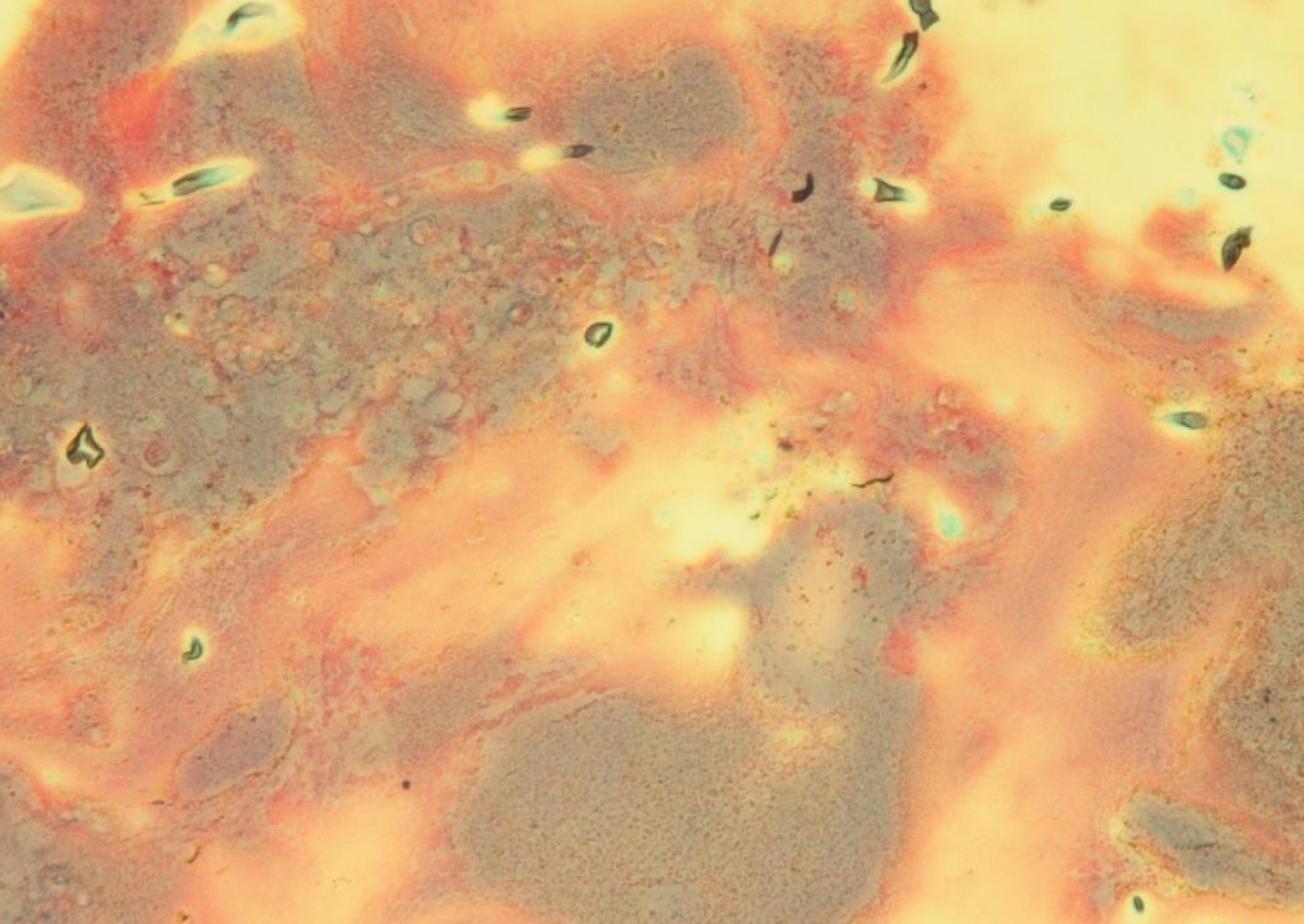
mycetoma, c/w aspergillosis [GMS stain]





c/w mucormycosis [PAS stain]





c/w mucormycosis [GMS stain]